

**TWENTY-SEVENTH EUROPEAN MEETING
ON DYSMORPHOLOGY**

**7 - 9 SEPTEMBER 2016
LE BISCHENBERG**

27th EUROPEAN MEETING ON DYSMORPHOLOGY

GENERAL PROGRAM

WEDNESDAY 7th SEPTEMBER

| | | |
|------------------------|--------|-------------------|
| 5 p.m. to 7.30 p.m. | | Registration |
| 7.30 p.m. to 8.30 p.m. | | Welcome reception |
| 8.30 p.m. | Dinner | |
| 9.30 p.m. | | Unknown [KD1] |

THURSDAY 8th SEPTEMBER

| | | |
|-------------------------|--------|----------------------------------|
| 8.15 a.m. | | Opening address |
| 8.30 a.m. to 1.00 p.m. | | First, second and third sessions |
| 1.00 p.m. | Lunch | |
| 2.30 p.m. to 7.00 p.m. | | Third session |
| 8.00 p.m. | Dinner | |
| 9.00 p.m. to 11.00 p.m. | | Unknown |

FRIDAY 9th SEPTEMBER

| | | |
|------------------------|--------|----------------------------|
| 8.30 a.m. to 1.00 p.m. | | Fourth and fifth sessions |
| 1.00 p.m. | Lunch | |
| 2.30 p.m. to 6.00 p.m. | | Sixth and seventh sessions |
| 7.30 p.m. | Dinner | |

SATURDAY 10th SEPTEMBER

Breakfast - Departure

SCIENTIFIC PROGRAM

Note: This program is tentative and may be modified.

WEDNESDAY 7th SEPTEMBER

9.30 UNKNOWN SESSION
Chair: VERLOES A.

L. BASEL VANAGAITE, K. DEVRIENDT AND NICOLE FLEISCHER
Workshop: Improving dysmorphology skills of new syndromes with computer aided analysis

THURSDAY 8th SEPTEMBER

08.30 Opening address: STUMPEL C.

08.45-10.00 FIRST SESSION: Craniofacial malformations and dysmorphology
Chair: STOLL C.

08.45 C. STOLL, Y. ALEMBIK, B. DOTT AND M.-P. ROTH
Associated anomalies in cases with anotia and microtia

09.00 D. LACOMBE, M. BERENGUER, E. LOPEZ, A. TINGAUD-SEQUEIRA, S. MARLIN, A. TOUTAIN, F. DENOYELLE, A. PICARD, S. CHARRON, G. MATHIEU, H. DE BELVALET, B. ARVEILER, P.J. BABIN AND C. ROORYCK
Mutations in *MYT1*, encoding the myelin transcription factor 1, are a rare cause of Goldenhar syndrome within the RA signaling pathway

09.15 A. VERLOES, D. HAYE, C. BAUMANN, A. TOUTAIN, D. BONNEAU, D. LEHALLE, P. CALLIER, S. DRUNAT, I. LUND, E. BHOJ, P. BOGAARD, S. LEENSKJOLD, E. ZACKAI, D. LI, H. HAKONARSON, M. PETERSEN AND I. NIELSEN
Phenotypic spectrum of *SPECC1L* mutations encompasses Teebi hypertelorism syndrome but not Opitz BBBG syndrome: report of new families and critical review of the literature

09.30 E. BRISCHOUX-BOUCHER, C. COLLET, C. CZORNY AND L. VAN MALDERGEM
Crouzon-like craniosynostosis in two siblings harboring *IL11RA* composite heterozygous mutations

09.45 J. ROOSENBOOM, I. SAEY, A. VERDONCK, V. VANDER POORTEN, T. DORMAAR, J. SCHOENAERS, K. DEVRIENDT, H. PEETERS, P. CLAES AND G. HENS
Facial morphology associated with isolated cleft palate

- 10.00-11.00 SECOND SESSION: Skeletal dysplasias
- 10.00 A. MATULEVIČIENĖ, L. AMBROZAITYTĖ, R. MATULEVIČIŪTĖ, A. LIUBŠYS, A. UTKUS AND V. KUČINSKAS
A patient with Raine syndrome due to novel mutations in *fam20c* gene
- 10.15 A. BAYAT, B. KERR AND S. DOUZGOU
The evolving cranio-facial phenotype and a bifid uvula in a patient with Sensenbrenner syndrome caused by *IFT140* compound heterozygous mutations
- 10.30 M. JEANNE, S. ALIROL, N. CHELLOUG, L. DRUART, E. TERRENOIRE, N. RONCE, M. RAYNAUD AND A. TOUTAIN
A new case of X;Y translocation further supports the existence of a growth control locus on the Y chromosome
- 10.45 K. STEINDL, P. JOSE, L. GOGOLL AND A. RAUCH
if not Albright hereditary osteodystrophy what is it? Biallelic variants in the *PRMT7* gene cause a novel syndrome with a distinct Albright-like phenotype
- 11.00-11.30 *Coffee Break*
- 11.30-12.30 THIRD SESSION: Clinical and genetic delineation of known syndromes (part 1)
Chair: LACOMBE D. - RAUCH A.
- 11.30 S. PASSEMARD, K. IZUMI, M. BRETT, E. NISHI, S. DRUNAT, E.-S. TAN, K. FUJIKI, S. LEBON, B. CHAM, K. MASUDA, M. ARAKAWA, A. JACQUINET, Y. YAMAZUMI, S.-T. CHEN, A. VERLOES, Y. OKADA, Y. KATOU, T. NAKAMURA, T. AKIYAMA, P. GRESSENS, R. FOO, E.-C. TAN, V. EL GHOUZZI AND K. SHIRAHIGE
ARCNI mutations in a dominant form of microcephalic dwarfism
- 11.45 M. ZENKER, D. SCHANZE, J. RAO, W. TAN, D. BRAUN, D. SCHAPIRO, F. HILDEBRANDT and the International *GAMOS* Consortium
Nephrotic syndrome with associated brain anomalies - new lessons on the heterogeneity of Galloway-Mowat syndrome
- 12.00 C. FAUTH, G. KROPSHOFER, A. SCHOSSIG, L. PÖLSLER, B. MEISTER and J. ZSCHOCKE
Prolidase deficiency - a rare autosomal recessive disorder associated with intellectual disability, short stature and facial dysmorphism case report of a 13-year-old boy
- 12.15 I. IVANOVSKI, S. ROSATO, I. MAINI, M. MUSSINI, K. STEINDL, M. ZWEIER, L. GARAVELLI AND A. RAUCH
A new case of Helsmoortel-van der Aa syndrome (ADNP-related intellectual disability and autism spectrum disorder)
- 12.30 L. GOGOLL, P. JOSET, K. STEINDL AND A. RAUCH
A new case of Ogden syndrome: a review on the clinical course and the natural history of a rare lethal X-linked recessive disorder
- AFTERNOON
- 14.30-16.00 THIRD SESSION: Clinical and genetic delineation of known syndromes (part 2)
Chair: BIJLSMA E. - BONATI M.T.

- 14.30 I. MEERSCHAUT, S. DE CONINCK, S. GARCIA MIÑAUR, J.C. OOSTERWIJK, R. IGBOKWE, M. SURI, A. BAYAT, G. JONES, C.I. DALI, S. LYNCH, E. BLAIR, A. COLLINS, V. LAITINEN, E. THOMAS, A. MALE, I. STOLTEDIJKSTRA, K. KEYMOLEN, L. CHERYL, D. YADAV, F. MCKENZIE, S. BERLAND, P. WILLEMS, A. TOPA, F. PETIT, A. DESTREE, J. DE BACKER, P.J. COUCKE, A. DE PAEPE, S. SYMOENS AND B. CALLEWAERT
Congenital contractural arachnodactyly: delineation of clinical diagnostic criteria
- 14.45 L. GARAVELLI, I. IVANOVSKI, S.G. CARAFFI, D. SANTODIROCCO, M. POLLAZZON, D.M. CORDELLI, E. ABDALLA, P. ACCORSI, M.P. ADAM, P. AJMONE, M. BADURA-STRONKA, C. BALDO, A. BAYAT, E. BELLIGNI, S. BIGONI, F. BONVICINI, J. BRECKPOT, B. CALLEWAERT, G. COCCHI, G. CUTURILO, D. DE BRASI, K. DEVRIENDT, M.B. DINULOS, O. DJURIC, T. DUELUND HJORTSHØJ, R. EPIFANIO AND F. FARAVELLI, A. FIUMARA, D. FORMISANO, L. GIORDANO, M. GRASSO, S. GRØNBORG, A. IODICE, L. IUGHETTI, V. KUBUROVIC, A. KUTKOWSKA-KAZMIERCZAK, D. LACOMBE, C. LO RIZZO, A. LUCHETTI, B. MALBORA, I. MAMMI, F. MARI, S. MOUTTON, R. MØLLER, P. MUSCHKE, E. OBERSZTYN, C. PANTALEONI, A. PELLICCIARI, M.A. PISANTI, M.L. POCH OLIVE, F. RAVI GLIONE, F. RIVIERI, S. SAVASTA, G. SCARANO, I. SCHANZE, A. SELICORNI, M. SILENGO, R. SMIGIEL, L. SPACCINI, G. SORGE, K. SZCZALUBA, L. TARANI, L. GONZAGA TONE, A. TOUTAIN, A. TRIMOUILLE, E. TERCI VALERA, S. SCHRIER VERGANO, N. ZANOTTA, M. ZENKER, M. ZOLLINO, C. ZWEIER, W.B. DOBYNS AND A.R. PACTORKOWSKI
Clinical findings in Mowat-Wilson syndrome: a study of 80 patients
- 15.00 A. KUECHLER, B. ALBRECHT, E. LEGIUS, N.C. BRAMSWIG, H.-J. LÜDECKE, T.M. STROM, D. WIECZOREK, M. ZENKER AND I. WIELAND
An adult female patient with ocular dermoid, calcifying meningeomas, hyperostosis of the skull, facial, alveolar and phalangeal exostoses and skin changes - a long way to the right diagnosis
- 15.15 K. KEYMOLEN, L. DE MEIRLEIR, M. DE RADEMAEKER, D. DANEELS, B. CALJON, S. VAN DOOREN, D. CROES AND E. LEGIUS
Overgrowth and intellectual disability: two more patients with DNMT3A mutations
- 15.30 A. VINCENT, V. GATINOIS, A. FAVREAU AND A. TOUTAIN
Pituitary stalk interruption syndrome in Kabuki syndrome: a case report and review of the literature
- 15.45 C. STUMPEL, J. NICOLAI, S. STEGMANN, K. OBERNDORFF, C. GEUSGENS, I. KEULARTS-KÖRVER AND E. RUBIO-GOZALBO
A girl with two mutations in PIGN: a challenging diagnosis
- 16..00-16.30 *Coffee Break*
- 16.30-17.30 THIRD SESSION: Clinical and genetic delineation of known syndromes (part 3)
Chair: STUMPEL C.- KOHLHASE J.
- 16.30 I. SLEGERS, M. LEYDER, K. VAN BERKEL, S.A. KLUIJFHOUT, M. CANNIE, C. STAESSEN, G. LEEMANS, A. JANSEN, M. DE RADEMAEKER, B. DIMITROV, M. BONDUELLE AND K. KEYMOLEN
Fetal (prenatal) features of PITT Hopkins syndrome - case report
- 16.45 D. BARTHOLDI, D. DOECKER, L. VOGEL, J. SCHUBERT, E.M. GOLDMANN AND S. BISKUP
Identification of a heterozygous *de novo* variant in the metabotropic glutamate receptor type 5 gene (*GRM5*) in a patient with non-syndromic intellectual disability - a novel rare cause of developmental disabilities?

- 17.00 I.K. NIELSEN, I.S. PEDERSEN, V.Q. LE, A. ERNST AND J.R. OSTERGAARD
Recurrence of *MEF2C* mutation in siblings with unusual communicative skills
- 17.15 D. MITTER, M. PRINGSHEIM, M. KAULISCH, K. PLÜMACHER, S. SCHRÖDER, D. MALZAHN,
B. ZIRN, K. BROCKMANN AND FOXG1-STUDY GROUP
FOXG1 syndrome: genotype-phenotype correlation in 84 patients with a *FOXG1* point mutation
- 17.30 KEY-NOTE LECTURE
A. BLOCH-ZUPAN
Amelogenesis imperfecta: lessons from NGS
- 21.00-23.00 UNKNOWN
Chair: VERLOES A. - DEVRIENDT K.
- K. AVELA, K. AALTONEN AND K. AITTO MÄKI
Formal unknown: An unknown case with growth hormone deficiency and dysmorphic features
- A. BOUMAN and P. LAKEMAN
A 36-year-old female with a Treacher Collins-like phenotype plus additional features

FRIDAY 9th SEPTEMBER

- 08.45-11.00 FOURTH SESSION: X-linked intellectual disability
Chair: VERLOES A. MIDRO A.
- 08.45 S. MOORTGAT, D. LEDERER, M. DEPREZ, M. BUZATU, S. BOULANGER, V. BENOIT, S. MARY
AND I. MAYSTADT
Expanding the phenotype of *OPHN1* mutations: three unrelated families with intellectual
disability and absence of cerebellar hypoplasia
- 09.00 S. MOORTGAT, J. DESIR, V. BENOIT, S. BOULANGER, H. PENDEVILLE, M.-C. NASSOGNE,
D. LEDERER AND I. MAYSTADT
Two Novel EIF2S3 mutations associated with X-linked syndromic intellectual disability with
severe microcephaly, growth retardation, and epilepsy
- 09.15 A. BOUMAN, M. ALDERS, L. VAN LEEUWEN, N. THUIJS AND M. VAN MAARLE
OFD1 in males: congenital heart defect can be included in its phenotypic spectrum
- 09.30 M. DE RADEMAEKER, L. DEMEIRLEIR, A.C. HOUTMAN, K. STOUFFS, B. CALJON, S. VAN
DOOREN, D. CROES AND K. KEYMOLEN
A *BCOR* variant in a male
- 09.45 N. DIKOW, M. GRANZOW, L.M. GRAUL-NEUMANN, S. KARCH, K. HINDERHOFER, N.
PARAMASIVAM, L.-J. BEHL, L. KAUFMANN, C. FISCHER, C. EVERS, M. SCHLESNER, R.
EILS, G. BORCK, C. ZWEIER, C.R. BARTRAM, J.C. CAREY AND U. MOOG
Phenotypic overlap in girls with *DDX3X* mutations and Toriello-Carey syndrome

- 10.00 O.M. VANAKKER, B. LAPAUW AND A. GEERTS
Two novel patients with an Xq28 duplication excluding *FMR1* and *MECP2*
- 10.15 J. KÖTTING, J. BEYGO, H.-J. LÜDECKE, K. BUITING AND A. KÜCHLER
5-year old boy with intellectual disability, dysmorphic facial features and EEG abnormalities showing an increased copy number within the region Xq28 containing a partial triplication
- 10.30 M.T. BONATI, F. VERDE, U. HLADNIK, L. CAMPANA, N. TICOZZI, L. MADERNA, C. COLOMBRITA, S. PAPA, P. BANFI AND V. SILANI
Occipital Horn syndrome in a 57 year-old man carrying a novel nonsense mutation in *ATP7A*: family report and literature review
- 10.45 A. VAN HAGEN, M. ELTING AND S. JANSEN
Mental retardation, (inner) ear malformations and dysmorphism; the expanding phenotype of MED12 related disorders
- 11.00-11.30 *Coffee Break*
- 11.30-12.30 FIFTH SESSION: Genetic testing in syndromology
Chair: GARAVELLI L. - PEETERS H.
- 11.30 A. SIFRIM, M.-P. HITZ, A. WILSDON, J. BRECKPOT, S.H. AL TURKI, B. THIENPONT, J. MCRAE, T.W. FITZGERALD, T.R. SINGH, G. JAWAHAR SWAMINATHAN, E. PRIGMORE, D. RAJAN, H. ABDUL-KHALIQ, S. BANKA, U.M.M. BAUER, J. BENTHAM, F. BERGER, S. BHATTACHARYA, F. BU'LOCK, N. CANHAM, I.-G. COLGIU, C. COSGROVE, H.N. COX, I. DAEHNERT, A. DALY, J. DANESH, A. FRYER, M. GEWILLIG, E. HOBSON, K. HOFF, T. HOMFRAY, THE INTERVAL STUDY, A.-K. KAHLERT, A. KETLEY, H.-H. KRAMER, K. LACHLAN, A.K. LAMPE, J.J. LOUW, A. KUMAR MANICKARA, D. MANASE, K.P. MCCARTHY, K. METCALFE, C. MOORE, R. NEWBURY-ECOB, S. OSMAN OMER, W.H. OUWEHAND, S.-M. PARK, M.J. PARKER, TH. PICKARDT, M. O POLLARD, L. ROBERT, D.J. ROBERTS, J. SAMBROOK, K. SETCHFIELD, B. STILLER, C. THORNBOROUGH, O. TOKA, H. WATKINS, D. WILLIAMS, M. WRIGHT, S. MITAL, P.E.F. DAUBENEY, B. KEAVNEY, J. GOODSHIP, THE UK10K CONSORTIUM, R. MAHDI ABU-SULAIMAN, S. KLAASSEN, C.F. WRIGHT, H.V. FIRTH, J.C. BARRETT, K. DEVRIENDT, D.R. FITZPATRICK, J.D. BROOK, THE DECIPHERING DEVELOPMENTAL DISORDERS STUDY AND M.E. HURLES
Distinct genetic architectures for syndromic and non-syndromic congenital heart defects identified by exome sequencing
- 11.45 Á. MARTÍN-RODRÍGUEZ, A. PRIETO-ABERASTURI, J. SÁNCHEZ AND A. GONZÁLEZ-MENESES
Usefulness of skin biopsy in the genetic diagnosis of mental retardation associated with skin pigmentary lesions
- 12.00 E. BIJLSMA, E. ATEN, D. FRANSEN VAN DE PUTTE, A. VAN HAERINGEN, N. DEN HOLLANDER, Y. HILHORST, S. KANT AND M. KOOPMANS, T. POTJER, M. HOFFER, C. RUIVENKAMP AND G. SANTEN
Unexpected diagnoses after whole exome sequencing
- 12.15 A. LUMAKA, V. RACE, H. PEETERS, P. LUKUSA AND K. DEVRIENDT
Clinical and molecular screening for the fragile X syndrome in specialized institutions in Kinshasa, DR Congo

AFTERNOON

- 14.30-15.45 SIXTH SESSION: Cytogenetics
Chair: CALLEWERT B. - KEYMOLEN K.
- 14.30 N. COSEMANS AND H. PEETERS
The clinical relevance of intragenic nrxn1 copy number variants
- 14.45 J. DE GEYTER, K. STEINDL, B. ONEDA AND A. RAUCH
New case confirms the role of CTNNB1 haploinsufficiency in intellectual disability
- 15.00 I. SCHANZE, S. BOPPUDI, S. BERLAND, M. GÉRARD, M. HOLDER-ESPINASSE, E. LACAZE, S. MORGAN, H. PEETERS, F. PETIT, D.T. PILZ, I. WIELAND, J.-B. RIVIÈRE, D. SCHANZE, L. FAIVRE AND M ZENKER
Haploinsufficiency of the NFIB gene in patients with mild intellectual disability
- 15.15 S.M. AZZARELLO-BURRI, P JOSET, J ANDRIEUX, F LOPES, E.E. PALMER, J.C. CZESCHIK, B. DEMEER, F. DUQUE, A. KÜCHLER, P. MACIEL, B. PLECKO, B. ONEDA AND A. RAUCH
Further Delineation of a novel 2q11.1q11.2 microduplication syndrome
- 15.30 R. NICOLESCU, J.-H. CABERG AND S. BULK
A family of Kagami-Ogata syndrome
- 15.45-16.15 *Coffee Break*
- 16.15-18.00 SEVENTH SESSION: Limb malformations
Chair: DEVRIENDT K.. - ZENKER A.
- 16.15 L. DARDOUR, J. BRECKPOT, P. MOENS, C. OOSTERLYNCK AND K. DEVRIENDT
FATCO syndrome: fibular hypoplasia, tibial campomelia and oligosyndactyly
- 16.30 P. THILOBO LUKUSA, L. DARDOUR, L. LEWI, P. MOERMAN AND K. DEVRIENDT
Confirmation of a distinct condition with severe limb deficiency, (mirror) polydactyly and variable organ malformations
- 16.45 A.T. MIDRO, J. BORYS, E. HUBERT, T. DAWIDZIUK, E. WASILEWSKA, J. SKOWRONSKI⁴, E. TARASÓW, B. PANASIUK, E.M. OLECH AND A. JAMSHEER
TAR syndrome with orofacial clefting - 30 years follow-up
- 17.00 J KOHLHASE, G SCHMIDT AND W BOROZDIN
Baller-Gerold, RAPADILINO and Rothmund-Thomson syndromes: case reports and mutations detected in our patient cohort
- 17.15 D. HAYE, E. AMOUYAL, C. BAUMANN1, Y. CAPRI, S. ROSSIGNOL, M.-P. MOIZARD, A. VERLOES AND L. PERRIN
Hepatoblastoma in a female with Simpson Golabi Behmel Syndrome: should we monitor females with SGBS as we do for males ?
- 17.30 A. BOTTANI
On the potential importance for a dysmorphologist to (sometimes) attend a wine fair: a true story !

WORKSHOP: IMPROVING DYSMORPHOLOGY SKILLS OF NEW SYNDROMES WITH COMPUTER AIDED ANALYSIS

L. BASEL VANAGAITE¹, K. DEVRIENDT² AND NICOLE FLEISCHER³

¹ Schneider Children's Medical Center and Beilinson Hospital, Rabin Medical Center, Felsenstein Medical Research Center, Petah Tikva, Israel; Tel Aviv University, Israel.

² Centre for Human Genetics, University Hospital, KU Leuven, Leuven, Belgium.

³ FDNA Inc., Boston, MA, USA.

E-mail for correspondence: nicole@fdna.com

Dysmorphology training is a real challenge. The rarer the syndrome, the lower the probability of a medical professional encountering that syndrome more than once. Computer-aided dysmorphology analysis enables the clinical geneticist to benefit from the cumulative knowledge of geneticists worldwide. This tool will allow workshop participants to receive a hands-on learning experience and test their dysmorphology knowledge and skills, mainly on relatively new syndromes.

This workshop will include a 10 min. overview of best practices in using computer-aided dysmorphology analysis followed by a 10 min. update on research using this technology. This will then be followed by 40 min. practical training using specific exercises /challenges on each participant's laptop/ tablet or phone. Participants will be able to use references and interconnected dysmorphology databases in solving these exercises /challenges. Q&A will be allowed throughout the practical exercises.

Attendees to the workshop will improve their skills in dysmorphology of new syndromes, will learn to recognize syndromes based on facial dysmorphic features aided by computer analysis and learn to interpret results of computer-aided dysmorphology analysis.

A 36-YEAR-OLD FEMALE WITH A TREACHER COLLINS-LIKE PHENOTYPE PLUS ADDITIONAL FEATURES

A. BOUMAN AND P. LAKEMAN

Clinical Genetics, AMC, The Netherlands.

E-mail for correspondence: a.bouman@amc.nl

Medical history: Bw: 1770 gr (<<-2.5 SD), BL: 43 cm (<<-2.5 SD), microcephaly, congenital hypothyroidism
Short stature: GH-treatment (@ 10 – 15 yrs), discrepancy in leg length + asymmetry
premature ovarian failure (@ 28 yrs).

Family history: Negative.

Physical exam: H: 149.5 (-2.5 SD), W: 48.0 kg (+1.5 SD), OFC: 47,8 (<<-2.5 SD)
Craniofacial: flat malar region, high frontal hairline, small, low set posteriorly rotated ears
Underdevelopment of the alae nasi / low columella, high arched palate, retrognathia.
Discrepancy in leg length, pes planovalgus, lumbar lordosis.

Investigations: Brain-MRI (@ 30 yrs): normal.
X-hand (@ 15 yrs): delay 1.5 yrs.
Ophthalmology exam: -5 Dpt bilateral.
Array-CGH: normal female profile.

DNA-diagnostics Treacher Collins: normal.

AN UNKNOWN CASE WITH GROWTH HORMONE DEFICIENCY AND DYSMORPHIC FEATURES

K. AVELA, K. AALTONEN AND K. AITTO MÄKI

Department of Clinical Genetics, Helsinki University Hospital, Finland

E-mail for correspondence: kristiina.avela@hus.fi

We present an unknown case with prenatal growth retardation and dysmorphic features. The patient was born to a healthy non-consanguineous couple with no family history of congenital diseases. A caesarean section was performed at h.35+6 due to growth retardation. At birth, the weight of the patient was 1915 g, height 42 cm (-2.8 SD), and OFC 33 cm. Due to the growth retardation a chromosomal analysis was performed, and a normal female karyotype was detected 46, XX.

Postnatally proportional growth retardation has been detected. The height of the patient has been -4.5 SD, and OFC at -0.5 SD. The psychomotoral development is normal.

The endocrinological work-up revealed a growth hormone deficiency, and the patient receives currently growth hormone replacement therapy, which has improved the growth. Brain MRI revealed hypoplasia of the pituitary gland. The ophthalmological examination revealed a chorioretinal coloboma in the left eye. The patient has chronic constipation.

A 3D-CT was performed as the shape of the skull is abnormal, the forehead is prominent and wide. A prematurely closed sagittal sutura was seen. All the other suturae were open. The dysmorphic features of the patient include also prominent ears, and hypertelorism.

The X-rays of the skeleton did not reveal signs of a bone dysplasia. The ultrasound analysis of the heart and abdomen gave normal results.

All the etiological examinations performed so far, including aCGH (Agilent 180K), UPD7, 11p15.5 methylation, FGFR1 exon 7, FGFR2 exons IIIa and IIIc, FGFR3 exons 7 and 10, TWIST exon 1, have given normal results.

ASSOCIATED ANOMALIES IN CASES WITH ANOTIA AND MICROTIA

C. STOLL, Y. ALEMBIK, B. DOTT AND M.-P. ROTH

Laboratoire de Génétique Médicale, Faculté de Médecine, 67085 Strasbourg Cedex, France.

Infants with anotia and microtia (AM) often have other non-AM associated congenital anomalies. The purpose of this investigation was to assess the prevalence and the types of these associated anomalies in a defined population. The associated anomalies in infants with AM were collected in all livebirths, stillbirths and terminations of pregnancy during 29 years in 387,067 consecutive births in the area covered by our population-based registry of congenital malformations. Of the 146 cases with AM registered during this period, representing a prevalence of 3.77 per 10,000, 49.3% had associated anomalies. There were 14 (9.6%) cases with chromosomal abnormalities including 5 trisomies 18, and 18 (12.3%) nonchromosomal recognized dysmorphic conditions including 6 cases with oculo-auriculo-vertebral spectrum. However, numerous other recognized dysmorphic conditions were registered. Forty (27.4%) of the cases had multiple congenital anomalies (MCA). Anomalies especially in the cardiovascular, the musculoskeletal, the urogenital, the central nervous, and the digestive systems, and facial clefts were the most common other anomalies. This study included special strengths: each affected child was examined by a geneticist, all elective terminations were ascertained, and the surveillance for anomalies was continued until 2 years of age. In conclusion the overall prevalence of associated anomalies, which was one in two cases, emphasizes the need for a thorough investigation of cases with AM. A routine screening for other anomalies may be considered in infants and in fetuses with AM.

MUTATIONS IN *MYT1*, ENCODING THE MYELIN TRANSCRIPTION FACTOR 1, ARE A RARE CAUSE OF GOLDENHAR SYNDROME WITHIN THE RA SIGNALING PATHWAY

D. LACOMBE^{1,6}, M. BERENQUER¹, E. LOPEZ¹, A. TINGAUD-SEQUEIRA¹, S. MARLIN², A. TOUTAIN³, F. DENOYELLE⁴, A. PICARD⁵, S. CHARRON¹, G. MATHIEU¹, H. DE BELVALET¹, B. ARVEILER^{1,6}, P.J. BABIN¹ AND C. ROORYCK^{1,6}

¹ INSERM U1211, MRGM, University of Bordeaux,

² Centre de Référence des Surdités Génétiques, CHU Necker-Enfants-Malades, Paris,

³ Service de Génétique, CHU Tours,

⁴ Centre de Référence des malformations ORL rares, CHU Necker-Enfants-Malades, Paris,

⁵ Service de chirurgie maxillo-faciale, CHU Necker-Enfants-Malades, Paris,

⁶ CHU de Bordeaux, Service de Génétique Médicale, Centre de Référence Anomalies du Développement et Syndromes Malformatifs, F-33076, Bordeaux, France

E-mail for correspondence. didier.lacombe@chu-bordeaux.fr

Goldenhar syndrome (GS) or Oculo-Auriculo-Vertebral Spectrum (OAVS) is a developmental disorder involving first and second branchial arches, characterized by asymmetric ear anomalies, hemifacial microsomia, ocular defects, and vertebral malformations. Although numerous chromosomal abnormalities have been associated with OAVS, no causative gene has been identified so far. Among other environmental factors, Retinoic Acid (RA) has already been described as a teratogenic agent leading to OAVS features in humans.

As sporadic cases are mostly described in GS, we have performed whole exome sequencing on selected affected individuals and their unaffected parents, looking for de novo mutations. Consequently, we identified a heterozygous nonsense mutation in one patient in the *MYT1* gene. Further, we detected one heterozygous missense mutation in another patient from a cohort of 169 OAVS patients. This gene encodes the Myelin Transcription factor 1 which is highly expressed in the developing central nervous system.

Functional studies by transient knockdown of *myt1a*, homolog of *MYT1* in zebrafish, led to specific craniofacial cartilages alterations and to the up-regulation of neural crest cells marker *sox10*. Moreover, cells studies confirmed close links between *MYT1*, RA and the RA receptor beta (RARβ). Indeed, All-trans RA (ATRA) treatment led to an upregulation of cellular endogenous MYT1 expression. Additionally, cellular wild-type MYT1 overexpression induced a down-regulation of RARβ leading to a negative feedback of the RA signaling pathway, whereas mutated MYT1 did not, confirming the pathogenic effect of the mutations.

Overall, we report *MYT1* as the first gene implicated in Goldenhar syndrome, within the RA signaling pathway.

PHENOTYPIC SPECTRUM OF *SPECC1L* MUTATIONS ENCOMPASSES TEEBI HYPERTELORISM SYNDROME BUT NOT OPITZ BBBG SYNDROME: REPORT OF NEW FAMILIES AND CRITICAL REVIEW OF THE LITERATURE

A. VERLOES¹, D. HAYE¹, C. BAUMANN¹, A. TOUTAIN², D. BONNEAU³, D. LEHALLE⁴, P. CALLIER⁴, S. DRUNAT¹, I. LUND⁵, E. BHOJ, P^{6,7}. BOGAARD⁸, S. LEENSKJOLD⁹, E. ZACKAJ⁶, D. LI⁷, H. HAKONARSON⁷, M. PETERSEN⁵ AND I. NIELSEN⁵

¹ Department of Genetics APHP-Robert DEBRE University Hospital, Paris;

² Department of Genetics, Bretonneau University Hospital, Tours;

³ Department of Genetics, University Hospital, Angers;

⁴ Department of Genetics, Children University Hospital, Dijon, France.

⁵ Department of Clinical Genetics, Aalborg University Hospital, Aalborg, Denmark.

⁶ Department of Genetics, Children's Hospital of Philadelphia, Philadelphia, PA, United States.

⁷ Center for Applied Genomics, Children's Hospital of Philadelphia, Philadelphia, PA, United States.

⁸ Department of Pathology, Aalborg University Hospital, Aalborg, Denmark.

⁹ Department of Gynecology and Obstetrics, Aalborg University Hospital, Aalborg, Denmark.

Anomalies of midline craniofacial development are observed in several syndromes that were originally delineated on clinical basis. Opitz BBBG syndrome was associated with mutations in *MID1*, Baraitser-Winter craniofrontofacial syndrome with mutations in *ACTB* and *ACTG1*, and recently, Teebi syndrome with mutations in *SPECC1L*. *SPECC1L* plays a role in in gap junctions involved in cell adhesion, in actin cytoskeleton organization, microtubule stabilization and spindle organization, and in cytokinesis. It modulates *PI3K-AKT* signaling and controls cranial neural crest cells delamination and facial morphogenesis. *SPECC1L* mutations were first identified in patients with oblique facial clefts (OBLFC1; OMIM 600251). Recently, mutations in *SPECC1L* were reported in a pedigree reported in 1988 as Opitz syndrome. We report three further pedigrees with *SPECC1L* syndrome, including a 3-generation family and one fetal case. Our patients confirm that *SPECC1L* syndrome is clinically similar to Teebi syndrome. Critical phenotypic analysis of previous patients published with *SPECC1L* and *MID1* mutations lead us to consider that *SPECC1L* syndrome should not be described as "dominant Opitz syndrome": hypospadias and laryngeal anomalies that characterizes Opitz syndrome are never observed with *SPECC1L* mutations, whereas branchial anomalies, parietal hernias, uterine anomalies or vascular anomalies characterize *SPECC1L* mutants.

CROUZON-LIKE CRANIOSYNOSTOSIS IN TWO SIBLINGS HARBORING *IL11RA* COMPOSITE HETEROZYGOUS MUTATIONS

E. BRISCHOUX-BOUCHER¹, C. COLLET², C. CZORNY³ AND L. VAN MALDERGEM¹

¹ Centre de Génétique Humaine, CHU St Jacques, Besançon, France.

² Service de Biochimie et Biologie Moléculaire, CHU Lariboisière, Paris, France.

³ Service de Neurochirurgie, CHU Jean-Minjoz, Besançon, France.

E-mails for correspondence: ebrischouxboucher@chu-besancon.fr; corinne.collet@aphp.fr; lvanmaldergem@chu-besancon.fr

We describe two siblings (9 year-old girl and 5 year-old boy), born to unrelated Algerian parents, with proptosis bulbi, brachycephaly and sharp skull resembling Crouzon syndrome. Severe chronic retro-orbital headache with nausea required neurosurgical craniectomy in the female sibling at age of 8. Syringomyelia and scoliosis are present from early age by her. No anomaly of the extremities is noted. Absence of disease-causing mutation in *FGFR2* prompted us to investigate a possible mutation in the newly discovered genes for autosomal recessive craniosynostosis resembling Crouzon syndrome. Among these, *IL11RA* (the gene coding for the alpha subunit of interleukin 11 receptor) occupies a prominent place. Interestingly, a missense variant c.328G>T in exon 4 resulting in p.Gly110Cys and a missense variant c.866A>G in exon 9 resulting in p.His289Arg were observed, classified as probably pathogen by prediction software (Mutation Taster, Polyphen-2). This observation is very similar to those of Niemenen *et al.* in 2011, who found that *IL11RA* function is to restrict suture fusion and tooth number. So the loss of its function cause craniosynostosis, delayed tooth eruption and supernumerary teeth, features that were described by his group in twelve subjects from five consanguineous families, all harboring *IL11RA*. In 2013, Keupp *et al.* described twelve other patients with Crouzon-like craniosynostosis without teeth abnormalities but with conductive hearing loss, a common feature in craniosynostosis patients. The two siblings we present here do have the Crouzon phenotype only. However, syringomyelia and scoliosis are unreported clinical features in one of them. In conclusion, apart from the well-known autosomal dominant *FGFR2*-related Crouzon syndrome, a small proportion of patients has a condition inherited according to an autosomal recessive mode of inheritance. Their phenotype is apparently not clinically distinctive.

FACIAL MORPHOLOGY ASSOCIATED WITH ISOLATED CLEFT PALATE

J. ROOSENBOOM¹, I. SAEY², A. VERDONCK^{3,4}, V. VANDER POORTEN^{4,5}, T. DORMAAR⁶, J. SCHOENAERS⁶, K. DEVRIENDT^{4,7}, H. PEETERS⁷, P. CLAES² AND G. HENS^{1,4,5}

¹ Department of Neurosciences, Research Group Experimental Otorhinolaryngology, Catholic University of Leuven, Leuven, Belgium

² Department of Electrical Engineering, Research Group Medical Image Computing, ESAT/PSI, Catholic University of Leuven, Leuven, Belgium

³ Department of Oral Health Sciences, University Hospitals Leuven, Leuven, Belgium

⁴ Multidisciplinary Cleft Lip and Palate Team, University Hospitals Leuven, Leuven, Belgium

⁵ Department of ORL, Head & Neck Surgery, University Hospitals Leuven, Leuven, Belgium

⁶ Department of Maxillofacial Surgery, University Hospitals Leuven, Leuven, Belgium

⁷ Center for Human Genetics, University Hospitals Leuven, Leuven, Belgium

E-mail for correspondence: koenraad.devriendt@uzleuven.be

This study aims to objectively describe facial morphology in patients with cleft palate (CP), using 3D surface imaging and advanced morphometrics.

In a prospective cohort study, we recruited 39 children (6-12 years) with isolated CP, 8 patients with Robin Sequence (RS) and 51 control subjects.

All subjects underwent 3D facial surface imaging. In addition, the available lateral cephalograms and panoramic radiographs were reviewed. 3D facial morphology was compared between patients with CP and RS, and control subjects. Cephalometric SNA, SNB and ANB angles were measured on lateral cephalograms. Panoramic radiographs were checked for tooth agenesis.

Patients with isolated CP show a distinct facial phenotype, compared to control subjects. Both patients with CP and patients with RS show a retrusion of the chin, consistent with cephalometric measurements. Patients with RS show additional effects on the lateral sides of the face and in the forehead region. They also have a significantly higher prevalence of tooth agenesis.

Our results indicate that children with CP and RS show a retrusion of the chin as compared to controls, and this effect was more pronounced in the patients with RS. On top of this effect, patients with RS show additional facial characteristics, and can be delineated as a separate group. 3D facial imaging and morphometrics seems an excellent tool to describe subtle facial phenotypes and to differentiate between two different phenotypes, such as CP and RS.

A PATIENT WITH RAINE SYNDROME DUE TO NOVEL MUTATIONS IN *FAM20C* GENE

A. MATULEVIČIENĖ^{1,2}, L. AMBROZAITYTĖ^{1,2}, R. MATULEVIČIŪTĖ³, A. LIUBŠYS^{4,5}, A. UTKUS^{1,2} AND V. KUČINSKAS^{1,2}

¹ Centre for Medical Genetics at Vilnius University Hospital Santariškių Klinikos, Vilnius, Lithuania

² Department of Human and Medical Genetics Faculty of Medicine, Vilnius University, Vilnius, Lithuania

³ Faculty of Medicine, Vilnius University, Vilnius, Lithuania

⁴ Centre of Neonatology, Children's Hospital, Affiliate of Vilnius University Hospital Santariškių Klinikos, Vilnius, Lithuania;

⁵ Centre of Neonatology, Clinics of Children's Diseases, Faculty of Medicine, Vilnius University, Vilnius, Lithuania

E-mail for correspondence: ausra.matuleviciene@mf.vu.lt

We report on a patient with skeletal dysplasia characterized by dysmorphic facial features, such as bilateral proptosis, mid-face hypoplasia, gum hypertrophy, and radiological findings including increased bone density and cerebral calcifications.

Our patient was a first-born male child of non-consanguineous parents. He was delivered at 40 weeks' gestation via Caesarean section, with Apgar scores of 5, 6, 7 at 1, 5 and 10 minutes respectively. His birth weight was 4020 g, birth length – 53 cm, occipitofrontal circumference – 34 cm, chest circumference – 35 cm. Due to poor condition, the newborn was intubated immediately after birth. Patient's phenotype suggested skeletal dysplasia. His dysmorphic features included turricephaly, flat face, expressed bilateral proptosis with everted bottom eyelids, down-slanted lateral corners of palpebral fissures, hypertelorism, severe depression of nasal bridge with small nose and severe mid-face hypoplasia, low-set ears, microstomia, gum hypertrophy, highly arched and narrow palate, micrognathia, short neck, and narrow chest with widely spaced nipples. Ultrasound of heart and internal organs revealed no anomalies. During the otorhinolaryngological examination, bilateral choanal atresia and partial cleft palate were diagnosed. Radiological findings included increased density of all bones, wide ribs, and flattened vertebrae bodies. Brain MRI showed diffuse cerebral calcifications (mostly around lateral ventricles and meninges), herniation of caudal part of the cerebellum through the foramen magnum. Patient died on the 18th day after birth.

Based on the phenotypic features and radiological findings of the patient, diagnosis of Raine syndrome was suspected. Raine syndrome is a very rare autosomal recessive disorder (prevalence of less than 1 in 1,000,000), characterized by craniofacial anomalies, generalized osteosclerosis with periosteal new bone formation, and brain abnormalities including cerebral calcifications, and is often considered lethal condition. There are around 40 cases of this syndrome described worldwide. Proptosis, mid-face hypoplasia, choanal atresia, micrognathia, and generalized osteosclerosis are main features that have been described in almost all previous reports of this condition. This syndrome is caused by mutations of *FAM20C* gene, which plays an important role in mineralization of bones and teeth during early development in rodent studies. Analysis of the coding sequences of *FAM20C* of the patient identified a novel deleterious/probably damaging heterozygous variant in exon 5 (c.1069T>C) and possibly damaging/tolerated homozygous variant in exon 10 (c.1672C>T). Patient's parents are currently undergoing molecular genetic testing of *FAM20C* gene to confirm their carrier status.

THE EVOLVING CRANIO-FACIAL PHENOTYPE AND A BIFID UVULA IN A PATIENT WITH SENSENBRENNER SYNDROME CAUSED BY *IFT140* COMPOUND HETEROZYGOUS MUTATIONS

A. BAYAT^{1,2}, B. KERR^{2,3} AND S. DOUZGOU^{2,3}

¹ Department of Pediatrics, University Hospital of Hvidovre, Kettegaard Alle 20, 2650, Hvidovre, Denmark.

² Manchester Centre for Genomic Medicine, Central Manchester University Hospitals NHS Foundation Trust, Manchester Academic Health Sciences Centre, St Mary's Hospital;

³ Institute of Human Development, University of Manchester, Oxford Road. Manchester, M13 9WL, UK.

E-mail for correspondence: allan.bayat@regionh.dk

Ciliopathies are a vast group of genetic disorders caused by altered cilia assembly, maintenance, or function. Mutations in genes that encode components of the intraflagellar transport complex A (IFT-A), which drives retrograde ciliary transport, are a major cause of skeletal ciliopathies. Alterations of all IFT-A components have been previously reported to cause Sensenbrenner, Jeune asphyxiating thoracic dystrophy (JATD), Mainzer-Saldino (MSS) and/or short-rib polydactyly syndromes (*IFT43* [MIM 614068], *IFT122* [MIM 606045], *IFT139* [MIM 612014], *IFT140* [MIM 614620], *IFT144* [MIM 608151], *WDR35* [MIM 613602]). Sensenbrenner syndrome, also known as cranioectodermal dysplasia, is a rare multiple anomaly syndrome with distinctive craniofacial appearance, skeletal, ectodermal, connective tissue, renal, and liver anomalies. The diagnosis is established in those with typical clinical findings and can be confirmed in 40% of affected individuals by identification of bi-allelic mutations in one of four genes known to be causing Sensenbrenner syndrome (*IFT122*, *WDR35*, *WDR19* or *IFT43*). Mutations in *IFT140* can result in a clinical phenotypic continuum ranging from isolated retinal dystrophy to MSS and, less commonly, JATD but it has not been described in patients with a clinical presentation of Sensenbrenner syndrome, so far.

We report the evolving facial phenotype in a child with compound heterozygosity for *IFT140* mutations and Sensenbrenner syndrome. We therefore propose that mutations in the *IFT140* gene may also cause Sensenbrenner syndrome and we present a bifid uvula as an additional feature of this syndrome.

A NEW CASE OF X;Y TRANSLOCATION FURTHER SUPPORTS THE EXISTENCE OF A GROWTH CONTROL LOCUS ON THE Y CHROMOSOME

M. JEANNE¹, S. ALIROL¹, N. CHELLOUG¹, L. DRUART², E. TERRENOIRE¹, N. RONCE¹, M. RAYNAUD AND¹ A. TOUTAIN¹

¹ Service de Génétique, CHRU Bretonneau, Tours, France.

² Laboratoire Biomnis, Paris, France.

E-mail for correspondence: mederic.jeanne@gmail.com

We report a new case of X;Y translocation in a phenotypically normal male patient. He was referred at the age of 6 for isolated short stature. His height was 105.3 cm (-2 SD) for a midparental height at -1 SD. Physical examination was normal. Endocrinological investigations showed no abnormalities, in particular, there was no GH or IGF1 deficiency. X-rays were normal except for mild bowing of the radii, without Madelung malformation or epiphyseal stippling. Bone age was mildly delayed. Standard chromosome analysis showed a female 46,XX karyotype but FISH analysis revealed an unbalanced X;Y translocation with the presence of SRY and SHOX on the derivative X chromosome whereas the probe DYZ3, mapping at Yp11.3, was absent. The final chromosomal formula was therefore 46,X,der(X)t(X;Y)(p22.3;p11.2). In order to characterize this rearrangement, we performed a microarray analysis with both male and female references (Agilent ISCA 180k). This confirmed the loss of the entire long arm of the chromosome Y and showed a 963 Kb deletion encompassing the gene ARSE at the breakpoint within the Xp22.33 region. The deletion was located at 2 Mb downstream to the SHOX gene. Quantitative PCR analysis confirmed the haploinsufficiency of ARSE.

These results raise the question of the mechanism of the short stature in our patient. It is not surprising that he was not affected by chondrodysplasia punctata, which is in keeping with the phenotype of heterozygous females, as this region escapes X inactivation. It has been reported that idiopathic short stature may be due to SHOX enhancers deletions. However, enhancers are located at most around 600 Kb downstream to the gene. It is therefore unlikely that the short stature in our patient is related to SHOX deficiency. Finally, the implication of the loss of the long arm of the Y chromosome must be discussed. Indeed, the existence of genetic factors regulating the height has been postulated on the observation of Y deletions. A 700 Kb critical region containing a growth control locus (GCY) has been defined at Yq12, but until now no gene has been identified.

IF NOT ALBRIGHT HEREDITARY OSTEODYSTROPHY WHAT IS IT? BIALLELIC VARIANTS IN THE PRMT7 GENE CAUSE A NOVEL SYNDROME WITH A DISTINCT ALBRIGHT-LIKE PHENOTYPE

K. STEINDL, P. JOSE, L. GOGOLL AND A. RAUCH

Institute of Medical Genetics, University of Zurich, Schlieren-Zurich, Switzerland.

E-mail for correspondence: steindl@medgen.uzh.ch

Compound heterozygous mutations in the *PRMT7* gene have been recently identified via the DDD study in six affected females from three different families. The associated phenotype is a phenocopy of the Albright hereditary osteodystrophy including characteristic symmetrical shortening of the digits, posterior metacarpals and metatarsals, postnatal growth failure, facial dysmorphism, intellectual disability and obesity. Here we report two new cases, a brother and a sister with biallelic variants in the *PRMT7* gene. We will present the clinical course and the evolving phenotypes of both patients in detail. By describing the first affected male so far, we are also focusing on the sexually dimorphic phenotype. We are further delineating the clinical spectrum by providing new features. In conclusion our report of two novel patients confirms the distinct Albright-like-phenotype in a novel syndrome associated with biallelic variants in the *PRMT7* gene.

ARCN1 MUTATIONS IN A DOMINANT FORM OF MICROCEPHALIC DWARFISM

S. PASSEMARD^{7,8,12}, K. IZUMI^{1,2,3}, M. BRETT⁴, E. NISHI^{2,5,6}, S. DRUNAT^{7,8}, E.-S. TAN⁹, K. FUJIKI¹, S. LEBON⁷, B. CHAM⁹, K. MASUDA¹, M. ARAKAWA², A. JACQUINET¹⁰, Y. YAMAZUMI¹¹, S.-T. CHEN¹, A. VERLOES^{7,8,12}, Y. OKADA¹³, Y. KATOU¹, T. NAKAMURA⁶, T. AKIYAMA¹¹, P. GRESSENS^{7,12,14}, R. FOO¹⁵, E.-C. TAN^{4,16}, V. EL GHOZZI^{7,12} AND K. SHIRAHIGE^{1,17}.

¹ Research Center for Epigenetic Disease, Institute for Molecular and Cellular Biosciences, The University of Tokyo, Tokyo;

² Division of Medical Genetics, Nagano Children's Hospital, Azumino, Japan.

³ Division of Human Genetics, The Children's Hospital of Philadelphia, Pennsylvania, Philadelphia, USA.

⁴ KK Research Centre, KK Women's and Children's Hospital, Singapore.

⁵ Department of Medical Genetics, Shinshu University Graduate School of Medicine, Matsumoto;

⁶ Life Science Research Center, Nagano Children's Hospital, Azumino, Japan.

⁷ INSERM UMR1141, Hôpital Robert Debré, Paris;

⁸ Département de Génétique, Hôpital Robert Debré, Paris, France.

⁹ Genetics Service, Department of Paediatrics, KK Women's and Children's Hospital, Singapore.

¹⁰ Département de Génétique, CHU et Université de Liège, Liège, Belgium.

¹¹ Laboratory of Molecular and Genetic Information, Institute of Molecular and Cellular Biosciences, University of Tokyo, Japan.

¹² Université Paris Diderot Paris 7, Hôpital Robert Debré, Paris, France.

¹³ Laboratory of Pathology and Development, Institute of Molecular and Cellular Biosciences, The University of Tokyo, Japan.

¹⁴ Center for Developing Brain, King's College, St. Thomas' Campus, London, United Kingdom;

¹⁵ Genome Institute of Singapore, Singapore.

¹⁶ Paediatrics ACP, SingHealth Duke-NUS Medical School, Singapore.

¹⁷CREST, Japan Science and Technology Agency, Kawaguchi, 332-0012, Japan.

**These authors contributed equally.

Coat protein I (COPI) is a heptameric protein complex required for retrograde transport of proteins and lipids from the Golgi apparatus (GA) to the endoplasmic reticulum (ER), a fundamental process critical to ensure homeostasis in the early secretory pathway. Recently, deleterious mutations in the COPI- α subunit of COPI have been reported to cause a hereditary autoimmune-mediated lung disease and arthritis, through an impairment of ER-GA transport associated with ER stress. Here, we report on 4 patients in 3 independent families with a newly described autosomal dominant form of microcephalic dwarfism, associated with micrognathia, cleft palate, cataract, shortening of forearms and legs, muscular build and mild intellectual delay. One of these patient was reported as a child with a purported "new" autosomal recessive disorder (Verloes *et al.*, Am J Med Genet 1997;68:455-460), and turned out to have an affected child. Exome sequencing revealed heterozygous loss-of-function mutations in *ARCN1*, the gene that encodes the COPI- α subunit of COPI. *ARCN1* haploinsufficiency affected the structure of the GA and induced ER stress response in patient's primary fibroblasts. These findings were confirmed in control skin fibroblasts where *ARCN1* was knocked down and in a cancer cell line where the gene was mutated using the CRISPR/Cas9 system. Our findings demonstrate the importance of COPI-mediated transport in human development, including skeletogenesis and brain growth.

NEPHROTIC SYNDROME WITH ASSOCIATED BRAIN ANOMALIES – NEW LESSONS ON THE HETEROGENEITY OF GALLOWAY-MOWAT SYNDROME

M. ZENKER¹, D. SCHANZE², J. RAO², W. TAN², D. BRAUN², D. SCHAPIRO², F. HILDEBRANDT² and the International GAMOS Consortium

¹ Institute of Human Genetics, University Hospital Magdeburg, Magdeburg, Germany.

² Division of Nephrology, Boston Children's Hospital, Harvard Medical School, Boston, MA, USA.

E-mail for correspondence: martin.zenker@med.ovgu.de

The eponymic name Galloway-Mowat syndrome (GAMOS; OMIM 251300) has been coined for the association of early-onset nephrotic glomerulopathy, microcephaly with variable brain anomalies, and facultative diaphragmatic hernia. It is supposed to be inherited as an autosomal recessive trait and clinical as well as genetic heterogeneity has been suggested. In 2014, WDR73 mutations were identified as a cause of GAMOS, but only a few cases have been reported to date.

Over the last 15 years, we have collected DNA samples and clinical data from 56 unrelated families with one or more children affected by GAMOS or a GAMOS-like syndrome (glomerulopathy plus variable anomalies of brain morphology or function as inclusion criteria), including 15 consanguineous families. We performed whole exome sequencing in selected, informative cases from this cohort and targeted analysis by Sanger and NGS multigene panel resequencing, respectively, in the remainder. This work was part of a large collaborative research effort to identify new genes for inherited kidney diseases (coordinated by F. H.).

In a total of 25 families of this cohort (45%) the probable underlying genetic defect could be identified. In affected individuals from two consanguineous families, homozygous mutations of WDR73 could be found (Vodopituz *et al.*, 2015). Thus, this gene accounted for only 4% of cases of our cohort. The affected child of another consanguineous family had a novel homozygous mutation in ARHGDI1. This gene has previously been described in three families to cause early-onset steroid-resistant nephrotic syndrome (Gupta *et al.*, 2013; Gee *et al.*, 2013), but there is some evidence that non-specific brain anomalies may also be part of the ARHGDI1-associated phenotype. Fourteen and three index patients from unrelated families had mutations in one autosomal and one X-linked gene, respectively, both encoding for components of a protein complex that has been implicated in transcription, telomere maintenance and chromosome segregation. No human phenotype has previously been assigned to mutations in this complex. Notably, eight unrelated families with an identical mutation originated from the East Asian population where according to ExAC the carrier frequency for this allele is 0.0008. In one consanguineous family with multiple affected children the disease segregated with a homozygous mutation in another novel gene. In four families, the kidney phenotype could be attributed to mutations in genes for non-syndromic nephrosis (NPHS1, PLCE1, one novel gene), while the brain phenotype was apparently independent.

In conclusion, the molecular genetic findings in this cohort confirmed that GAMOS is exceedingly heterogeneous; and still in more than half of the patients with a GAMOS-like phenotype the genetic cause remained unclear. On the basis of the achievements of this collaborative research we are now able to define new biologic mechanisms that are critically involved in both, brain development and integrity of the glomerular filtration barrier. Genotype phenotype correlations are emerging. Finally, we demonstrate that GAMOS can also be inherited as an X-linked trait.

PROLIDASE DEFICIENCY - A RARE AUTOSOMAL RECESSIVE DISORDER ASSOCIATED WITH INTELLECTUAL DISABILITY, SHORT STATURE AND FACIAL DYSMORPHISM CASE REPORT OF A 13-YEAR-OLD BOY

C. FAUTH¹, G. KROPSHOFER², A. SCHOSSIG¹, L. PÖLSLER¹, B. MEISTER² AND J. ZSCHOCKE¹

¹ Division of Human Genetics, Medical University Innsbruck, Austria.

² Department of Pediatrics I, Medical University Innsbruck, Austria.

E-mail for correspondence: christine.fauth@i-med.ac.at

Prolidase deficiency is a rare autosomal recessive disorder caused by mutations in PEPD (peptidase D = prolidase). The main clinical feature is therapy resistant ulceration of the skin, particularly of the legs. Other symptoms include mild to moderate intellectual disability, recurrent respiratory infections, haematological abnormalities, hepatosplenomegaly, short stature and facial dysmorphism. The course of the disease is variable and skin manifestations may not necessarily be the first symptom which may lead to a delay in diagnosis.

Here, we report on a 13-year-old boy with mild intellectual disability, short stature, recurrent respiratory infections, hearing loss due to bilateral tympanic membrane perforation, and facial dysmorphism (widely spaced eyes, proptosis, flat midface, short nose). Since the age of 9 the boy had developed recurrent hypochromic anaemia, mild thrombocytopenia, leukopenia, and hepatosplenomegaly the latter being attributed to a persistent EBV infection. Except from perioral dermatitis there were no skin manifestations. Molecular karyotyping and genetic testing for Aarskog syndrome had already been performed several years ago with normal results. As no diagnosis could be made on clinical grounds, exome analysis was performed. The patient was found to be compound heterozygous for an already described splice site mutation and a second previously unknown mutation in the PEPD gene leading to the diagnosis of prolidase deficiency.

This case illustrates the variable clinical presentation of prolidase deficiency and the difficulties in making the diagnosis in patients who lack the classical skin phenotype.

A NEW CASE OF HELSMOORTELVAN DER AA SYNDROME (ADNP-RELATED INTELLECTUAL DISABILITY AND AUTISM SPECTRUM DISORDER)

I. IVANOVSKI^{1,2}, S. ROSATO¹, I. MAINI^{1,3}, M. MUSSINI¹, K. STEINDL, M. ZWEIER⁴, L. GARAVELLI¹ AND A. RAUCH⁴

¹ Clinical Genetics Unit, Department of Obstetrics and Pediatrics, Arcispedale Santa Maria Nuova-IRCCS, Reggio Emilia, Italy.

² Department of Surgical, Medical, Dental and Morphological Sciences with Interest in Transplant, Oncology and Regenerative Medicine, University of Modena and Reggio Emilia, Modena, Italy.

³ Child Neuropsychiatry Unit, Arcispedale Santa Maria Nuova-IRCCS, Reggio Emilia, Italy.

⁴ Institute of Medical Genetics, University of Zurich, Zurich, Switzerland.

E-mail for correspondence: ivanovski.ivan@asmn.re.it

Helsmoortel-Van der AA syndrome (HVDAS, OMIM 615873) (ADNP-related intellectual disability and autism spectrum disorder) is a rare autosomal dominant disorder, characterized by mild to severe intellectual disability, speech ranging from no words to sentences, autism spectrum disorder (ASD), and a characteristic facial appearance which includes prominent forehead, high anterior hairline, ptosis, up- or downslanting palpebral fissures, wide nasal bridge, short nose, thin vermilion of the upper lip and small appearance of the mouth. Other common findings include hypotonia, seizures, feeding difficulties, behavioural problems, sleep disturbance, congenital heart diseases and visual problems. To date, HVDAS has been described in twenty-four patients.

Here, we report a 5-year-old female patient, born of Moroccan non-consanguineous parents, who was referred to our Unit at birth due to presence of hypotonia, congenital heart disease (atrial and ventricular septal defects), feeding difficulties, facial dysmorphisms, overlapping toes and 2nd-3rd syndactyly. During the follow-up she presented psychomotor developmental delay with the absence of speech, episodes of auto and hetero aggressiveness, and abnormalities of brain MRI (global reduction of supratentorial white matter and callosal hypoplasia). Using Whole Exome Sequencing and subsequent targeted sequencing, we identified the *de novo* c.2157C>A transition in the ADNP gene. The detected mutation is predicted to result in a premature stop codon at amino acid 719 of the protein (p.(Tyr719*)), leading therefore most probably to a nonfunctional allele product. To our knowledge the detected mutation c.2157C>A has not been reported so far, but another exchange on the same nucleotide position (c.2157C>G) predicted to result in the identical stop mutation p.Tyr719* has been already identified in two patients with a phenotype comprising ID/Developmental delay and other features.

A NEW CASE OF OGDEN SYNDROME: A REVIEW ON THE CLINICAL COURSE AND THE NATURAL HISTORY OF A RARE LETHAL X-LINKED RECESSIVE DISORDER

L. GOGOLL, P. JOSET, K. STEINDL AND A. RAUCH

Institute of Medical Genetics, University of Zurich, Schlieren-Zurich, Switzerland.

E-mail for correspondence: gogoll@medgen.uzh.ch

Ogden syndrome is a rare perinatal lethal X-linked recessive disorder characterized by a distinctive phenotype including postnatal growth failure, global severe developmental delay, facial dysmorphism, an aged appearance with reduced subcutaneous fat, skin laxity, structural cardiac anomalies and/or arrhythmias. Ogden syndrome was the first reported human genetic disorder associated with a mutation in an N-terminalacetyltransferase (NAT) gene. So far eight affected males from two different families are described in the literature, all harboring the same variant, a Ser37Pro (S37P) missense mutation in the gene encoding Naa10, the catalytic subunit of NatA, the major human NAT involved in the co-translational acetylation of proteins. Here we report a new case of Ogden syndrome. We have identified the specific mutation in a three month old boy of non-consanguineous parents of German and Polish origin. We were able to follow his clinical course, delineate the evolving phenotype until his unfortunate death at 7 months. We could confirm the associated phenotype, as well as the natural history of this severe disease. By describing new presenting features we are further expanding the clinical spectrum associated with NAA10 mutations.

CONGENITAL CONTRACTURAL ARACHNODACTYLY: DELINEATION OF CLINICAL DIAGNOSTIC CRITERIA

I. MEERSCHAUT¹, S. DE CONINCK¹, S. GARCIA MIÑAU², J.C. OOSTERWIJK³, R. IGBOKWE⁴, M. SURI⁵, A. BAYAT⁶, G. JONES⁷, C.I. DALI⁶, S. LYNCH⁸, E. BLAIR⁹, A. COLLINS¹⁰, V. LAITINEN¹¹, E. THOMAS¹², A. MALE¹³, I. STOLTEDIJKSTRA³, K. KEYMOLEN¹⁴, L. CHERYL¹⁵, D. YADAV¹⁶, F. MCKENZIE¹⁷, S. BERLAND¹⁸, P. WILLEMS¹⁹, A. TOPA²⁰, F. PETIT²¹, A. DESTREE²², J. DE BACKER¹, P.J. COUCKE¹, A. DE PAEPE¹, S. SYMOENS¹ AND B. CALLEWAERT¹

- ¹ Center for Medical Genetics, Ghent University Hospital, Ghent, Belgium.
- ² Clinical Genetics dpt, University Hospital la Paz, Madrid, Spain.
- ³ Dpt of genetics, University Medical Center Groningen, the Netherlands.
- ⁴ West Midlands Clinical Genetics Unit, Birmingham Women's NHS Foundation Trust, Birmingham, United Kingdom.
- ⁵ Nottingham Clinical Genetics Service Nottingham University Hospitals NHS Trust, Nottingham, United Kingdom.
- ⁶ Clinical Genetic Clinic, Kennedy Center, Copenhagen University Hospital, Denmark.
- ⁷ Clinical Genetics Department, University Hospitals of Leicester NHS Trust, Leicester, United Kingdom.
- ⁸ Department of clinical genetics, Our Lady's Children & Temple street Hospitals, Dublin, Ireland.
- ⁹ Oxford University Hospitals NHS Trust Churchill Hospital, Oxford, United Kingdom
- ¹⁰ Wessex Clinical Genetics Service University Hospital Southampton NHS Foundation Trust Princess Anne Hospital, Southampton, United Kingdom.
- ¹¹ Fimlab Laboratories, Tampere, Finland.
- ¹² Genetics clinic, Borough Wing Guy's Hospital Great Maze Pond, London, United Kingdom.
- ¹³ Clinical Genetics dpt, Great Ormond street hospital, London, United Kingdom.
- ¹⁴ Center for Medical Genetics, Brussels University Hospital, Brussels, Belgium.
- ¹⁵ Clinical genetics dpt, NHS Greater Glasgow & Clyde, Glasgow, United Kingdom.
- ¹⁶ Dpt of Pediatrics, Jawaharlal Institute of Postgraduate Medical Education and Research, Pondicherry, India.
- ¹⁷ Genetic Services of Western Australia, Subiaco, Australia.
- ¹⁸ Center for Medical Genetics and Molecular Medicine Haukeland University Hospital, Bergen, Norway.
- ¹⁹ Gendia, Antwerp, Belgium.
- ²⁰ Dpt of Clinical Genetics, Sahlgrenska University Hospital, Göteborg, Sweden.
- ²¹ Dpt for clinical Genetics, CHU de Lille, Lille, France.
- ²² Center for Human Genetics, Institute for Pathology and Genetics, Gosselies, Belgium.

E-mail for correspondence: Bert.Callewaert@Ugent.be

Congenital contractural arachnodactyly (CCA) is an autosomal dominant connective tissue disorder manifesting joint contractures, arachnodactyly, crumpled ears, and scoliosis as main features. Its rarity and substantial overlap with other conditions including Bethlem myopathy, Marfan syndrome and distal arthrogyroses, make the diagnosis challenging, though important for clinical management. CCA is caused by mutations in FBN2. We performed a comprehensive clinical and molecular assessment in a large cohort of CCA patients to delineate clinical diagnostic criteria and guide molecular analyses for FBN2. FBN2 analysis using either Sanger Sequencing or PCR-based next-generation sequencing was performed in 122 clinically well-characterized probands. We collected data on the 10 main clinical characteristics, and determined the sensitivity, specificity, and positive and negative predictive value to find an FBN2 mutation for each feature in order to establish a weighted clinical scoring system on 20 points. Forty-seven probands harbored an FBN2 mutation (mutation uptake rate 39%). All but 2 mutations were located in the neonatal region (exons 22-36) with half of them altering or producing cysteines. Two patients carried in-frame multi-exon deletions, one had a premature truncating mutation. Logistic regression analysis revealed a significantly higher clinical score in FBN2+ versus FBN2- patients (resp. 11,6 vs 7,7; $p < 0,001$). ROC curve analysis revealed that a clinical score of 11+ yields a sensitivity of 84% and a specificity of 60% to find an FBN2 mutation. A score of 6 or lower is unlikely to be associated with an FBN2 mutation, unless in adult patients. In addition, review of cardiovascular features revealed non- or slowly progressive aortic root dilatation in 5 FBN2+ patients and 6 FBN2- patients. Though aortic root dilatation is a non-discriminative feature, its occurrence in CCA does warrant echocardiographic follow-up.

CLINICAL FINDINGS IN MOWAT-WILSON SYNDROME: A STUDY OF 80 PATIENTS

L. GARAVELLI^{1*}, I. IVANOVSKI^{1,2*}, S.G. CARAFFI^{3*}, D. SANTODIROCCO¹, M. POLLAZZON¹, D.M. CORDELLI⁴, E. ABDALLA^{5,6}, P. ACCORSI⁷, M.P. ADAM⁸, P. AJMONE⁹, M. BADURA-STRONKA¹⁰, C. BALDO¹¹, A. BAYAT^{12,13}, E. BELLIGNI¹⁴, S. BIGONI¹⁵, F. BONVICINI^{1,16}, J. BRECKPOT¹⁷, B. CALLEWAERT¹⁸, G. COCCHI¹⁹, G. CUTURILO^{20,21}, D. DE BRASI²², K. DEVRIENDT¹⁷, M.B. DINULOS²³, O. DJURIC¹, T. DUELUND HJORTSHØJ²⁴, R. EPIFANIO²⁵, F. FARAVELLI²⁶, A. FIUMARA²⁷, D. FORMISANO²⁸, L. GIORDANO⁷, M. GRASSO¹¹, S. GRØNBORG²⁹, A. IODICE³⁰, L. IUGHETTI¹⁶, V. KUBUROVIC³¹, A. KUTKOWSKA-KAZMIERCZAK³², D. LACOMBE^{33,34}, C. LO RIZZO³⁵, A. LUCHETTI³⁶, B. MALBORA³⁷, I. MAMMI³⁸, F. MARI³⁵, S. MOUTTON^{33,39}, R. MØLLER^{40,41}, P. MUSCHKE⁴², E. OBERSZTYN³², C. PANTALEONI⁴³, A. PELLICCIARI⁴, M.A. PISANTI⁴⁴, M.L. POCH OLIVE⁴⁵, F. RAVIGLIONE⁴⁶, F. RIVIERI⁴⁷, S. SAVASTA⁴⁸, G. SCARANO⁴⁹, I. SCHANZE⁴², A. SELICORNI^{50,51}, M. SILENGO¹⁴, R. SMIGIEL⁵², L. SPACCINI⁵³, G. SORGE⁵⁴, K. SZCZALUBA³², L. TARANI⁵⁵, L. GONZAGA TONE⁵⁶, A. TOUTAIN⁵⁷, A. TRIMOUILLE³³, E. TERCI VALERA⁵⁶, S. SCHRIER VERGANO^{58,59}, N. ZANOTTA²⁵, M. ZENKER⁴², M. ZOLLINO⁶⁰, C. ZWEIER⁶¹, W.B. DOBYNS^{62,63} AND A.R. PACIORKOWSKI^{64,65,66,67}

- ¹ Clinical genetics Unit, Department of Obstetrics and Pediatrics, Arcispedale Santa Maria Nuova-IRCCS, Reggio Emilia, Italy.
- ² Department of Surgical, Medical, Dental and Morphological Sciences with interest in Transplant, Oncology and Regenerative Medicine, University of Modena and Reggio Emilia, Italy.
- ³ Laboratory of Translational Research, Arcispedale Santa Maria Nuova-IRCCS, Reggio Emilia, Italy.
- ⁴ Child Neurology and Psychiatry Unit, S Orsola Malpighi Hospital, University of Bologna, Italy.
- ⁵ Department of Medical Genetics, Faculty of Medicine, King Abdulaziz University, Jeddah, SA.
- ⁶ Department of Human Genetics, Medical Research Institute, University of Alexandria, Egypt.
- ⁷ Neuropsychiatric Department, Spedali Civili Brescia, Italy.
- ⁸ Division of Genetic Medicine, University of Washington School of Medicine, Seattle, USA.
- ⁹ Neuropsychiatric at Child and Adolescent Neuropsychiatric Service (UONPIA) Fondazione IRCCS Ca' Granda Ospedale Maggiore Policlinico, Milan, Italy.
- ¹⁰ Chair and Department of Medical Genetics, Poznan University of Medical Sciences, Poznań, Poland.
- ¹¹ Laboratory of Human Genetics; Galliera Hospital, Genoa, Italy.
- ¹² Department of Pediatrics, University Hospital of Copenhagen/Hvidovre, Denmark.
- ¹³ Department of Clinical Genetics, Rigshospitalet, University Hospital of Copenhagen, Denmark;
- ¹⁴ Department of Paediatrics, University of Torino, Torino, Italy.
- ¹⁵ Medical Genetic Unit, Ferrara University Hospital, Ferrara, Italy.
- ¹⁶ Pediatric Unit, Department of Medical and Surgical Sciences for Mothers, Children and Adults, University of Modena and Reggio Emilia, Modena, Italy.
- ¹⁷ Center for Human Genetics, Catholic University of Leuven, Belgium.
- ¹⁸ Center for Medical Genetics, Ghent University Hospital, Ghent, Belgium.
- ¹⁹ Neonatology Unit, S. Orsola-Malpighi Hospital, University of Bologna, Bologna, Italy.
- ²⁰ Faculty of Medicine, University of Belgrade, Belgrade, Serbia.
- ²¹ Department of Medical Genetics, University Children's Hospital, Belgrade, Serbia.
- ²² Pediatric Unit, AORN "A. Cardarelli", Naples, Italy.
- ²³ Department of Pediatrics, Dartmouth-Hitchcock Medical Center, Lebanon, NH, USA.
- ²⁴ Kennedy Center, Glostrup, Denmark.
- ²⁵ Clinical Neurophysiology Unit, IRCCS, E Medea Scientific Institute, Bosisio Parini, Lecco, Italy.
- ²⁶ Clinical Genetics, NE Thames Regional Genetics Service, Great Ormond Street Hospital for Children NHS Foundation Trust, London, UK.
- ²⁷ Department of Clinical and Experimental Medicine, Regional Referral Center for Inborn Errors Metabolism, Pediatric Clinic, University of Catania, Catania, Italy.
- ²⁸ Scientific Directorate, Arcispedale Santa Maria Nuova-IRCCS, Reggio Emilia, Italy.
- ²⁹ Center for Rare Diseases, Department of Clinical Genetics, University Hospital Copenhagen, Denmark.
- ³⁰ Neuropsychiatric Department, Arcispedale Santa Maria Nuova-IRCCS, Reggio Emilia, Italy.
- ³¹ Department of Cardiology, Mother and Child Health Care Institute, Belgrade, Serbia.
- ³² Department of Medical Genetics, Institute of the Mother and Child, Warsaw, Poland.
- ³³ Génétique médicale, CHU, Bordeaux, France.
- ³⁴ INSERM U1211, Univ. Bordeaux, Bordeaux, France.
- ³⁵ Medical Genetics, University of Siena, Siena, Italy.
- ³⁶ Child Neuropsychiatry Unit, Faculty of Medicine and Psychology, Sapienza University, Rome, Italy.
- ³⁷ Department of Pediatric Hematology & Oncology, Tepecik Training and Research Hospital, Izmir, Turkey.
- ³⁸ Medical Genetics Unit, Dolo Hospital, Venice, Italy.
- ³⁹ CHU Bordeaux, Centre de référence des anomalies du développement embryonnaire, Service de Génétique médicale, Bordeaux, France.
- ⁴⁰ Danish Epilepsy Centre, Dianalund, Denmark.
- ⁴¹ Institute for Regional Health Services, University of Southern Denmark, Odense, Denmark.
- ⁴² Institute for Human Genetics, University Hospital Magdeburg, Germany.
- ⁴³ Developmental Neurology Department, IRCCS Fondazione Istituto Neurologico "C. Besta," Milan, Italy.
- ⁴⁴ Medical Genetic Unit, AORN Cardarelli, Naples, Italy.
- ⁴⁵ Department of Pediatrics, H. San Pedro, La Rioja, Logrono, Spain.
- ⁴⁶ Clinical Neurophysiology and Epilepsy Center, Carlo Besta Neurological Institute, IRCCS, Milan, Italy.
- ⁴⁷ Genetics Unit, St Chiara Hospital, Trento, Italy.
- ⁴⁸ Department of Pediatrics, IRCCS San Matteo, Pavia, Italy.
- ⁴⁹ Department of Medical Genetics, Gaetano Rummo Hospital, Benevento, Italy.
- ⁵⁰ Department of Pediatrics, Hospital S. Gerardo, University of Milano-Bicocca, Monza, Italy.

- ⁵¹ Department of Pediatrics, ASST Lariana, Como, Italy.
⁵² Department of Genetics, Wroclaw Medical University, Wroclaw, Poland.
⁵³ Fetal Therapy Unit, Department of Obstetrics and Gynaecology, Children's Hospital V. Buzzi, Milan, Italy.
⁵⁴ Department of Pediatrics and Medical sciences, "Vittorio Emanuele" Hospital, University of Catania, Catania, Italy.
⁵⁵ Department of Pediatrics, University "La Sapienza," Rome, Italy.
⁵⁶ Department of Pediatrics, Ribeirão Preto Medical School, University of São Paulo, São Paulo, Brazil.
⁵⁷ Department of Genetics, Tours University Hospital, Tours, France.
⁵⁸ Department of Pediatrics, Eastern Virginia Medical School, Norfolk, Virginia, USA.
⁵⁹ Division of Medical Genetics and Metabolism, Children's Hospital of The King's Daughters, Norfolk, Virginia, USA.
⁶⁰ Institute of Genomic Medicine, Catholic University, Gemelli Hospital Foundation, Roma, Italy.
⁶¹ Institute of Human Genetics, Friedrich-Alexander-Universität Erlangen-Nürnberg (FAU), Erlangen, Germany.
⁶² Department of Pediatrics and Department of Neurology, University of Washington, Seattle, USA.
⁶³ Center for Integrative Brain Research, Seattle Children's Research Institute, Seattle, USA.
⁶⁴ Department of Pediatrics, University of Rochester Medical Center, Rochester, NY, USA.
⁶⁵ Department of Neurology, University of Rochester Medical Center, Rochester, NY, USA;
⁶⁶ Department of Biomedical Genetics, University of Rochester Medical Center, Rochester, NY, USA.
⁶⁷ Center for Neural Development and Disease, University of Rochester Medical Center, Rochester, NY, USA

E-mail for correspondence: garavelli.livia@asmn.re.it

Mowat-Wilson syndrome (MWS) is a genetic disease characterized by distinctive facial features, moderate to severe intellectual disability and congenital malformations including Hirschsprung disease, genital and eye anomalies and congenital heart defects, caused by haploinsufficiency of the ZEB2 gene. We examined the clinical findings of 80 patients, 42 males and 38 females with MWS: the most common clinical characteristics of the facial phenotype (>70% of the patients) were uplifted ear lobes, rounded nasal tip, prominent columella, broad nasal bridge, hypertelorism, fine hair, open mouth, M-shaped upper lip and prominent chin. The most frequent congenital heart diseases (each one >24% of the patients) were persistent ductus arteriosus (PDA), atrial septal defect (ASD) and ventricular septal defect (VSD). 61% of the patients had at least one heart anomaly. Three patients had an unusual malformation, consisting of pulmonary artery sling. Other reports confirmed that pulmonary artery sling, with or without tracheal stenosis, is not rare in MWS. Among the gastrointestinal manifestations constipation was the most frequent (73% of the patients) and Hirschsprung disease was demonstrated in 31%, with a double proportion of males compared to females ($p=0.011$), like in the general population. Among urogenital anomalies hypospadias was present in 68% and cryptorchidism in 57% of the cases. As regards eye anomalies strabismus was the most frequent (55% of the patients) but some patients also had ocular malformations, such as Axenfeld anomaly and microphthalmia. The incidence of astigmatism was more than double in females compared to males ($p=0.021$). The most common skeletal anomalies (more than 50% of the cases) were slender fingers, long toes and pes planus. Joint contractures were present in 13% of the cases with a clear prevalence of males over females. The most frequent cutaneous anomalies (each one >12% of the patients) were areas of hyperpigmentation, areas of hypopigmentation and deep palmar and plantar creases. Dental anomalies were frequent (each one more than 35% of the cases): widely spaced teeth, delayed tooth eruption and malpositioned teeth. Other frequent features (each one more than 30% of the cases) were high arched palate and recurrent otitis media. We also note the repeated vomiting attacks (19% of the cases) and hearing loss, more frequently of a conductive nature (11% of the patients) compared to sensorineural (5%). Regarding the behavioural phenotype, we underline the most common traits: they are affectionate and agreeable children with peculiar characteristics such as chewing and mouthing objects (72% of the patients), grinding teeth (66% of the patients) and switching lights on and off, more frequent in males than in females ($p=0.003$). Furthermore low reaction to pain should be taken into consideration (65% of the cases). To date, no characteristic pattern of brain dysmorphology in MWS has been defined through brain MRI analysis, we delineate a neuroimaging phenotype in 54 MWS patients with a proven ZEB2 defect, compare it with the features identified in a thorough review of published cases, and evaluate genotype-phenotype correlations. Results: 96% of a patients had abnormal MRI. The most common features were anomalies of corpus callosum (79.6% of cases), hippocampal abnormalities (77.8%), enlargement of cerebral ventricles (68.5%), white matter abnormalities (reduction of thickness 40.7%, localized signal alterations 22.2%). Other consistent findings were large basal ganglia, cortical and cerebellar malformations. Most features were underrepresented in the literature. We also found ZEB2 variations leading to synthesis of a defective protein to be favourable for psychomotor development and some epilepsy features, but also associated with corpus callosum agenesis. Conclusion: This study delineates the spectrum of brain anomalies in MWS and at the same time adds new insights in elucidating the role of ZEB2 in neurodevelopment.

AN ADULT FEMALE PATIENT WITH OCULAR DERMOID, CALCIFYING MENINGEOMAS, HYPEROSTOSIS OF THE SKULL, FACIAL, ALVEOLAR AND PHALANGEAL EXOSTOSES AND SKIN CHANGES - A LONG WAY TO THE RIGHT DIAGNOSIS

A. KUECHLER¹, B. ALBRECHT¹, E. LEGIUS², N.C. BRAMSWIG¹, H.-J. LÜDECKE^{1,3}, T.M. STROM^{4,5}, D. WIECZOREK^{1,3}, M. ZENKER AND⁶ I. WIELAND⁶

¹ Institut für Humangenetik, Universitätsklinikum Essen, Universität Duisburg-Essen, Essen, Germany.

² Center for Human Genetics, UZ Leuven, Leuven, Belgium.

³ present address: Institut für Humangenetik, Universitätsklinikum Düsseldorf, Heinrich-Heine-Universität Düsseldorf, Düsseldorf, Germany.

⁴ Institute of Human Genetics, Helmholtz Zentrum München, Neuherberg, Germany.

⁵ Institute of Human Genetics, Technische Universität München, Munich, Germany.

⁶ Institut für Humangenetik, Universitätsklinikum Magdeburg, O. von Guericke-Universität, Magdeburg, Germany.

E-mail for correspondence: alma.kuechler@uni-due.de

We report on a female patient who first presented at our department at the age of 21 years. She was referred with multiple different tentative diagnoses (i.e. neurofibromatosis, TRPS1, Dyke-Davidoff-Masson syndrome, hyperostosis syndrome, Gardner syndrome) due to her varied clinical signs. After normal infancy and childhood, first signs occurred during puberty: She developed an ocular dermoid, then exostoses at the fingers and in the face (frontal, paranasal), subsequently hyperostoses of the skull and tumours of the gingival or alveolar region. Moreover, operations were necessary for intracranial calcifying meningiomas. Skin changes, mainly lentiginos and 2 café-au-lait spots, occurred as well. Molecular analyses in blood revealed a normal result for molecular karyotyping and no relevant variant in whole exome sequencing (trio approach).

Finally, the working diagnosis Proteus syndrome was established, and molecular analyses regarding the recurrent *AKT1* mutation (p.Glu17Lys) were performed in available different tissue specimen (clinically surely affected, possibly affected, and not affected samples). This revealed a high level of mosaic state for the mutation c.49G>A, (p.Glu17Lys) in *AKT1* in affected tissue from bone and in meningioma. Re-evaluation of the NGS data from blood confirmed the absence of that mutation in all reads.

In conclusion, a somatic mosaicism leading to a mild Proteus phenotype could be confirmed as the underlying genetic cause of the condition in this female. Proteus syndrome (OMIM 176920) is an asymmetric disproportionate overgrowth syndrome with a highly variable phenotype affecting different tissues in different body parts depending on the time of occurrence during development.

OVERGROWTH AND INTELLECTUAL DISABILITY: TWO MORE PATIENTS WITH DNMT3A MUTATIONS

K. KEYMOLEN¹, L. DE MEIRLEIR¹, M. DE RADEMAEKER², D. DANEELS¹, B. CALJON¹, S. VAN DOOREN¹, D. CROES¹ AND E. LEGIUS³

- ¹ Centre for Medical Genetics, Reproduction and Genetics, Reproduction Genetics and Regenerative Medicine, Vrije Universiteit Brussel (VUB), UZ Brussel, Laarbeeklaan 101, 1090 Brussel, Belgium
- ² Department of Child Neurology, Vrije Universiteit Brussel (VUB), UZ Brussel, Laarbeeklaan 101, 1090 Brussel, Belgium
- ³ Department of Human Genetics, Catholic University Leuven/University Hospital Leuven, Herestraat 49, 3000 Leuven, Belgium

E-mail for correspondence: Kathelijm.Keymolen@uzbrussel.be

We present two unrelated men with overgrowth, intellectual disability, orthopedic problems and dysmorphism.

Both patients have non-consanguineous parents and unaffected sibs.

Birth weight was high in the two boys and developmental delay became obvious in early infancy.

Intellectual disability was diagnosed in both men.

They showed joint laxity with recurrent patella dislocations requiring surgery and one of the two also had elbow dislocations. Myopia was observed in both men. Facial appearance was characterized by heavy eyebrows and narrow palpebral fissures. Tall stature and macrocephaly were striking.

One of the patients had surgery for an atrial septal defect, strabismus and bilateral inguinal hernia, whereas the other one was operated for bilateral cryptorchidism, cholecystectomy and varicose veins in the legs.

At the age of 34 years, one of the men developed generalized edema with effusion in the pleural, pericardial and peritoneal cavities. Frontotemporal epilepsy was diagnosed at the same time. He died at the age of 36 years, probably secondary to heart failure.

The second patient developed an intraocular melanoma at the age of 27 years.

Mutations in DNMT3A were demonstrated in the two men. Their phenotype is comparable to the patients described by Tatton-Brown *et al.* (Nat Genet. 2014 April; 46(4): 385–388). The limited number as well as the younger age of the patients in the Tatton-Brown paper, make it impossible to say whether the severe complications in adulthood in the present two men are coincidental or related to the mutation. Long-term observation is thus mandatory to get better insights in the natural history of this syndrome.

PITUITARY STALK INTERRUPTION SYNDROME IN KABUKI SYNDROME: A CASE REPORT AND REVIEW OF THE LITERATURE

A. VINCENT¹, V. GATINOIS², A. FAVREAU³ AND A. TOUTAIN^{1,4}

¹ Service de Génétique, Centre Hospitalo-Universitaire, Tours, France.

² Laboratoire de Génétique Moléculaire, Centre Hospitalo-Universitaire, Montpellier, France.

³ Service de Néonatalogie, Centre Hospitalo-Universitaire, Tours, France.

⁴ Unité INSERM U930, Faculté de Médecine, Université François Rabelais, Tours, France.

Kabuki Syndrome (KS) (OMIM #147920) is a rare syndrome characterized mainly by distinctive facial features, multiple congenital anomalies and intellectual deficiency. Growth failure is reported in about 50% of patients. However, the cause of short stature is not elucidated in most of the patients. A few patients presenting endocrinological involvement of the hypothalamo-pituitary axis and only three with malformations of the pituitary gland or hypothalamus have been reported in the literature, two of them having a pituitary stalk interruption syndrome. We report a patient with KS who initially presented with persistent neonatal hypoglycaemia. A brain MRI performed at the age of 13 days showed a pituitary stalk interruption syndrome (PSIS) with an ectopic lobe of the pituitary gland and absence of the pituitary stalk. This new clinical report combined with an extensive review of the literature highlights the fact that abnormalities of the hypothalamo-pituitary axis should be looked for, and brain imaging of the pituitary gland should be performed, in all KS patients presenting growth retardation and/or abnormal levels of pituitary hormones. Precise and early diagnosis is important for the management of the patients as catch-up of the growth can be obtained with growth hormone treatment and the other complications of the hypothalamo-pituitary axis deficiency can be avoided.

A GIRL WITH TWO MUTATIONS IN PIGN: A CHALLENGING DIAGNOSIS

C. STUMPEL¹, J. NICOLAI², S. STEGMANN¹, K. OBERNDORFF³, C. GEUSGENS¹, I. KEULARTS-KÖRVER¹ AND E. RUBIO-GOZALBO⁴

¹ Department of Clinical Genetics and School for Oncology & Developmental Biology (GROW), Maastricht University Medical Center (MUMC), Maastricht, The Netherlands.

² Department of Neurology, MUMC, Maastricht, The Netherlands.

³ Department of Pediatrics, Zuyderland Medical Center Sittard, The Netherlands.

⁴ Department of Pediatrics and Clinical Genetics, MUMC, Maastricht, The Netherlands.

E-mail for correspondence: c.stumpel@mumc.nl

The second daughter of healthy, non-consanguineous Dutch parents presented with an extra nipple and distal hypoplasia of some digits. Facial dysmorphisms at the beginning was reminiscent of Pallister - Killian syndrome, but that suggestion could be excluded. At the age of 4 months, she suddenly developed partial complex seizures and, on the same day, secondary generalized seizures with tonic contractions and apnea. The seizures were treated with diazepam, midazolam and phenobarbital. After she was discharged, she used levetiracetam and phenobarbital and was seizure free. An electroencephalography showed a normal background pattern, multifocal epileptiform activity and no electroencephalographic seizures. Development appeared to be delayed and facial dysmorphism will be shown. In addition, she showed marked hypotonia. An MRI made at the age of 5-month showed a normal anatomy and normal myelination according to her chronological age. At the age of 13-month, the MR was repeated and again showed normal anatomy and normal myelination. This time a MR spectroscopy was performed; this revealed normal results as well. Additional metabolic testing in blood and urine showed no abnormalities. Flow cytometric studies are in progress.

Whole exome sequencing (targeted gene panels for Intellectual Disability and epilepsy) revealed compound heterozygous PIGN (phosphatidylinositol glycan class N, OMIM: 606097) variants; a paternally inherited p.Arg785His substitution and a maternally inherited p.Tyr249Cys substitution. Both variants affect conserved amino acid positions in functional domains of the PIGN protein

PIGN is one of the genes involved in the glycosylphosphatidylinositol (GPI)-anchor biosynthesis and remodeling pathway. GPI anchors tether proteins to the extracellular face of eukaryotic plasma membranes. Deficiencies in this pathway are a new subclass of congenital disorders of glycosylation, PIGN mutations have been described as causal for 'multiple congenital anomalies-hypotonia-seizures syndrome 1' (MCAHS1, OMIM: 61408).

This diagnosis was bad news and extra attention was given to psychological coping.

Vitamin B6 (pyridoxine) has been reported to be beneficial in some GPI deficient patients. At the age almost 14 months, after the lumbar puncture, treatment was started with pyridoxin 20 mg/kg/day.

We discuss the literature available so far. Differential diagnosis includes Pallister - Killian syndrome and Fryns syndrome, in which PIGN mutations recently were reported to cause the phenotype!

FETAL (PRENATAL) FEATURES OF PITT HOPKINS SYNDROME - CASE REPORT

I. SLEGERS¹, M. LEYDER², K. VAN BERKEL¹, S.A. KLUIJFHOUT¹, M. CANNIE³, C. STAESSEN¹, G. LEEMANS⁴, A. JANSEN⁵, M. DE RADEMAEKER¹, B. DIMITROV¹, M. BONDUELLE¹ AND K. KEYMOLEN¹

¹ Centre for Medical Genetics, UZ Brussel, Belgium.

² Department of Obstetrics and Prenatal Medicine, UZ Brussel, Belgium.

³ Department of Radiology, UZ Brussel, Belgium.

⁴ Department of Pathology, UZ Brussel, Belgium.

⁵ Department of Paediatrics, UZ Brussel, Belgium.

E-mail for correspondence: BoyanIvanov.Dimitrov@uzbrussel.be

Pitt-Hopkins syndrome is a rare genetic condition caused by *TCF4* gene mutations/ deletions on chromosome 18q. Affected individuals have severe developmental delay, dysmorphic features, specific breathing pattern abnormalities and seizures. The clinical features of more than 150 molecularly confirmed patients, children and adults, have been published allowing good delineation of the postnatal clinical spectrum. At least on two occasions diagnostic strategies for molecular testing of affected individuals have been proposed but both being recently sceptically reviewed regarding their efficiency. It is little known about the foetal (prenatal) features of Pitt-Hopkins syndrome. But with the availability of powerful prenatal methods for foetal imaging and genetic testing, the foetal dysmorphology will become more and more important in our daily clinical work. Thus the prenatal imaging data, genetic testing results and clinical features of a 22 weeks foetus with Pitt-Hopkins syndrome are presented and discussed in respect to the proper genetic counselling and diagnostic approach in prenatal settings.

IDENTIFICATION OF A HETEROZYGOUS *DE NOVO* VARIANT IN THE METABOTROPIC GLUTAMATE RECEPTOR TYPE 5 GENE (*GRM5*) IN A PATIENT WITH NON-SYNDROMIC INTELLECTUAL DISABILITY – A NOVEL RARE CAUSE OF DEVELOPMENTAL DISABILITIES?

D. BARTHOLDI¹, D. DOECKER², L. VOGEL³, J. SCHUBERT⁴, E.M. GOLDMANN⁵ AND S. BISKUP²

E-mail for correspondence: Deborah.Bartholdi@insel.ch

¹ University Children's Hospital, CH-3010 Bern, Switzerland.

² Praxis für Humangenetik Tübingen, D-72076 Tübingen, Germany.

³ Kinderarzt-Praxis Gersbach 1, D-74589 Satteldorf, Germany.

⁴ Dept. of Neurology and Epileptology, Hertie Institute for Clinical Brain Research, D-72076 Tübingen, Germany.

⁵ CeGaT, Center for Genomics and Transcriptomics, D-72076 Tübingen, Germany.

Whole exome sequencing (WES) is a powerful tool to identify the genetic basis of patients with developmental delay. Here we describe a female patient with moderate to severe intellectual disability and behavioural abnormalities without major dysmorphic features. We performed trio WES and identified the heterozygous missense variant *c.707C>T*; p.Ala236Val in the *GRM5* gene. Segregation analysis showed that the variant had most likely arisen *de novo* in the patient.

Alterations in glutamatergic signalling have been proposed in the aetiology of different neurodevelopmental disorders, e.g. intellectual disability (ID) and autism spectrum disorders (ASD).

Special focus has been paid to the role of the metabotropic glutamate receptor 5 (mGluR5) and its downstream effectors, since mutations in several interactors of mGluR5 are associated with ID or ASD. Examples are *SHANK3* and *FMR1*, the latter being the causative gene in fragile X syndrome. FMRP was shown to negatively regulate mGluR5 activity and clinical studies with different mGluR5 receptor antagonists have been performed in patients with fragile X syndrome.

To the best of our knowledge, the patient described here is the first individual reported so far carrying a variant in *GRM5*. The phenotype is similar to fragile X syndrome, suggesting that heterozygous mutations in the *GRM5* gene might be a rare cause of fragile X syndrome like ID/ASD. To determine the effect of the variant on the function of the mGluR5 receptor we will perform *in vitro* electrophysiological analyses of the *c.707C>T GRM5* variant using a voltage-clamp oocyte testing system. The results of these analyses were still pending at the time of the submission of this abstract.

RECURRENCE OF *MEF2C* MUTATION IN SIBLINGS WITH UNUSUAL COMMUNICATIVE SKILLS

I.K. NIELSEN¹, I.S. PEDERSEN², V.Q. LE², A. ERNST² AND J.R. OSTERGAARD³

¹ Department of Clinical Genetics, Aalborg University Hospital, Aalborg, Denmark.

² Section of Molecular Diagnostics, Clinical Biochemistry, Aalborg University Hospital, Aalborg, Denmark.

³ Department of Pediatrics, Aarhus University Hospital, Aarhus, Denmark.

E-mail for correspondence: irene.kibaek.nielsen@rn.dk

MEF2C haploinsufficiency syndrome (MIM #613443) is characterised by severe intellectual disability with absent speech, limited walking abilities, hand stereotypies, epilepsy, and lack of major malformations. *MEF2C* is essential for early neurogenesis, neuronal migration, and differentiation of the brain. To date, all individuals reported have been simplex cases, resulting from de novo deletions or point mutations. We present a case with putative gonadal mosaicism in a parent leading to siblings with *MEF2C* haploinsufficiency syndrome.

The family consists of healthy unrelated parents and female siblings (2 and 10 yrs) with a similar phenotype characterised by severe intellectual disability, absent spoken language, few seizures, stereotypic hand movements, unstable wide-based gait, and minor facial dysmorphism. The children have undergone intensive physical training and communicative training in a family setting. The eldest is able to communicate to a certain extent with letters/spelling and the youngest with pictograms.

Whole exome sequencing detected a pathogenic heterozygous frame-shift mutation in *MEF2C*:c.582delT in lymphocytes from both girls but not in lymphocytes from any of the parents. The parents did not wish to have any other samples taken in order to confirm a somatic or germline parental mosaicism. Mutations were validated by Sanger sequencing.

Finding the same mutation in siblings, and not in the parents, indicates parental gonadal mosaicism. To the authors' knowledge, this has not been described before for *MEF2C* haploinsufficiency syndrome, suggesting that the recurrence risk, for parents with a child with this syndrome, might be higher than by chance alone. Consideration of mosaicism should be part of the genetic counseling of these families. Furthermore, the level of nonverbal communicative skills achieved by these siblings widens the phenotype. Further investigations of this are needed.

FOXG1 SYNDROME: GENOTYPE-PHENOTYPE CORRELATION IN 84 PATIENTS WITH A FOXG1 POINT MUTATION

D. MITTER¹, M. PRINGSHEIM², M. KAULISCH³, K. PLÜMACHER⁴, S. SCHRÖDER⁴, D. MALZAHN⁵, B. ZIRN⁶, K. BROCKMANN⁷ AND FOXG1-STUDY GROUP

¹ Institute of Human Genetics, University Hospital Leipzig, Leipzig, Germany.

² Klinik für Neuropädiatrie und Neurologische Rehabilitation, Epilepsiezentrum für Kinder und Jugendliche, Schön Klinik Vogtareuth, Germany.

³ Leipzig, Germany.

⁴ Klinik für Kinder- und Jugendmedizin, Universitätsmedizin Göttingen, Germany.

⁵ Department of Genetic Epidemiology, University Medical Center, Georg-August University Göttingen, Göttingen, Germany.

⁶ Genetikum Stuttgart, Germany.

⁷ SPZ, Klinik für Kinder- und Jugendmedizin Universitätsmedizin Göttingen, Germany.

E-mail for correspondence: Diana.Mitter@medizin.uni-leipzig.de

Our study on patients with FOXG1 syndrome aimed at widening the clinical and genetic spectrum and at assessing genotype-phenotype correlations in patients with a FOXG1 point mutation. We compiled a series of 31 new and 53 previously reported patients with a heterozygous point mutation in the forkhead box G1 (*FOXG1*) gene. Statistical analysis of molecular, clinical and neuroradiological data was performed using Fisher's exact test and a nonparametric multivariate test. Taken all 84 patients together, there were 55 different mutations including 20 frameshift (36%), 18 missense (33%), 15 nonsense (27%), and two in-frame mutations (4%). Mutations were distributed over all FOXG1 protein domains, the 5' terminal proline- and glutamine-rich domain, the highly conserved forkhead DNA-binding domain including conserved site 1, and the 3' terminal domain. For genotype-phenotype correlation we established mutation groups according to the type and localisation of the mutations.

We found a higher phenotypic variability in the patients with FOXG1 syndrome in our study group than expected from previous reports. Genotype-phenotype analysis revealed significant differences in psychomotor development and neurological features between the different genotype groups. More severe phenotypes were associated with truncating *FOXG1* mutations in the 5' domain and the forkhead domain (except conserved site 1) and mildest phenotypes were found in patients with missense mutations in the forkhead conserved site 1. These data serve for improved interpretation of new *FOXG1* sequence variants and well-founded genetic counselling.

AMELOGENESIS IMPERFECTA: LESSONS FROM NGS

M.K. PRASAD¹, H. DOLLFUS^{1,2}, M. HUCKERT^{1,3,5}, M. SWITALA^{3,5} AND A. BLOCH-ZUPAN^{3,4,5,6,7}

- ¹ Laboratoire de Génétique Médicale, INSERM U1112, Fédération de Médecine Translationnelle de Strasbourg (FMTS), Université de Strasbourg, France.
- ² Centre de Référence pour les Affections Rares en Génétique Ophtalmologique, Service de Génétique Médicale, HUS, Strasbourg, France.
- ³ Université de Strasbourg, Faculté de Chirurgie Dentaire, Strasbourg, France.
- ⁴ Université de Strasbourg, Institut d'Etudes Avancées, USIAS, Strasbourg, France.
- ⁵ Hôpitaux Universitaires de Strasbourg (HUS), Pôle de Médecine et Chirurgie Bucco-dentaires, Centre de Référence des Manifestations Odontologiques des Maladies Rares, Strasbourg, France.
- ⁶ Institut de Génétique et de Biologie Moléculaire and Cellulaire - Centre Européen de Recherche en Biologie et en Médecine, Université de Strasbourg, IGBMC-CERBM CNRS UMR7104, INSERM U964, Illkirch, France.
- ⁷ Eastman Dental Institute, UCL, London, UK.

E-mail for correspondence: agnes.bloch-zupan@unistra.fr

Amelogenesis imperfecta (AI) is a clinically and genetically heterogeneous group of diseases characterised by enamel defects. To date, mutations in >20 genes have been implicated in either isolated or syndromic AI. We used a next-generation sequencing (NGS) panel "Genodont" targeting 585 known or candidate genes in dental disorders to screen a cohort of patients with isolated and syndromic forms of AI. We were able to identify the molecular defect underlying the patients' phenotypes in 17 different conditions. Many patients were undiagnosed, suggesting that additional genes mutation producing AI have yet to be identified. Interestingly, mutations in *COL17A1* were the most frequent cause of isolated AI in our cohort, accounting for 80% of all patients with isolated AI.

Furthermore, NGS-based screening of multiple AI genes allowed us to identify a rare case of digenic inheritance in AI, with unlinked heterozygous mutations in *COL17A1* and *LAMA3* modifying the severity of the phenotype. Phenotypic and genotypic heterogeneity of AI can exist, even within a single consanguineous family, segregating different clinical subtypes of hypoplastic and hypomineralised AI caused by 2 different distinct genes (*COL17A1* and *C4orf26*) mutations respectively.

Recognizing syndromic AI is critical for overall patient management. The orodental clinical and radiographic features of Enamel Renal syndrome (ERS) caused by *FAM20A* mutations are pathognomonic of this condition.

Sequencing DNA from a seven-year-old patient presenting with isolated AI revealed a homozygous missense mutation in *CNNM4*, a mutation producing Jalili syndrome, Ophthalmological investigation subsequently confirmed this diagnosis. We also identified that mutations in *LTBP3* were responsible for Verloes Bourguignon syndrome or the association between short stature, brachyolmia and AI.

Therefore, we demonstrate substantial genetic heterogeneity in AI being of unknown origins and that non-Mendelian inheritance patterns do exist. Genotype/phenotype correlations might be used to reclassify the current clinical classification of amelogenesis imperfecta. The dental clinic hence serves as a gateway for the diagnosis and management of rare genetic disorders.

This work was funded through: the University Hospital of Strasbourg (HUS, API, 2009-2012, 'Development of the oral cavity: from gene to clinical phenotype in Human', PHRC 2008 No4266 Amelogenesis imperfecta), the EU-funded projects: (ERDF) A27 'Oro-dental manifestations of rare diseases, supported by the RMT-TMO Offensive Sciences initiative, INTERREG IV Upper Rhine program (www.genosmile.eu) and by the INTERREG V N° 1.7 "RARENET" project.

EXPANDING THE PHENOTYPE OF *OPHN1* MUTATIONS: THREE UNRELATED FAMILIES WITH INTELLECTUAL DISABILITY AND ABSENCE OF CEREBELLAR HYPOPLASIA

S. MOORTGAT¹, D. LEDERER¹, M. DEPPEZ^{1,2}, M. BUZATU³, S. BOULANGER¹, V. BENOIT¹, S. MARY¹ AND I. MAYSTADT¹

¹ Centre de Génétique Humaine, Institut de Pathologie et de Génétique, Charleroi (Gosselies), Belgique.

² Département de Neuro-pédiatrie, Clinique Sainte-Elisabeth, Namur, Belgique.

³ Département de Neuro-pédiatrie, Hôpital Civil Marie Curie, Charleroi, Belgique.

E-mail for correspondence: Damien.lederer@ipg.be

The oligophrenin I gene (*OPHN1*, MIM #300127) is located on Xq12 and encodes a Rho-GTPase-activating protein involved in the regulation of the G-protein cycle. Rho protein members play an important role in dendritic growth and in plasticity of excitatory synapses. Mutations in *OPHN1* have been identified in patients with X-linked intellectual disability (XLID) associated with cerebellar hypoplasia and ventriculomegaly, suggesting a recognizable syndromic intellectual disability. Patients often share other clinical findings such as seizures, strabismus, ataxic gait, behavioral difficulties and slight facial dysmorphism with a long face, deep set eyes with pronounced infraorbital creases, short philtrum and prominent chin.

We report on three unrelated families affected by mild to severe intellectual disability due to *OPHN1* mutations where brain MRI did not reveal any cerebellar anomaly. We describe clinical, genetic and neuroimaging data of affected patients. We discuss the intrafamilial clinical variability and compare our patients with those previously reported. We emphasize the power of next generation techniques (X-exome sequencing and/or target multi gene panel) to expand the phenotypic and mutational spectrum of XLID caused by *OPHN1*.

TWO NOVEL EIF2S3 MUTATIONS ASSOCIATED WITH X-LINKED SYNDROMIC INTELLECTUAL DISABILITY WITH SEVERE MICROCEPHALY, GROWTH RETARDATION, AND EPILEPSY

S. MOORTGAT¹, J. DESIR², V. BENOIT¹, S. BOULANGER¹, H. PENDEVILLE³, M.-C. NASSOGNE⁴, D. LEDERER¹ AND I. MAYSTADT¹

¹ Centre de Génétique Humaine, Institut de Pathologie et de Génétique, Charleroi (Gosselies), Belgium.

² Centre de Génétique Humaine, Hôpital Erasme, Université Libre de Bruxelles (ULB), Brussels, Belgium.

³ GIGA-Research, Zebrafish Platform, Tour B34, Université de Liège, Liège (Sart-Tilman), Belgium.

⁴ Département de Neuropédiatrie, Cliniques Universitaires Saint-Luc, Brussels, Belgium.

E-mail for correspondence: stephanie.moortgat@ipg.be

We describe two unrelated families with suspected X-linked inheritance in which affected boys presented with similar clinical features consisting of severe intellectual disability, microcephaly and epilepsy. They also had growth retardation, micropenis and episodes of hypoglycemia. By X-exome sequencing, we identified a missense variant c.777T>G, p.(Ile259Met) in *EIF2S3* in the first family and a frameshift variant c.1394_1397del, p.(Ile465Serfs*4) in the same gene in the second family.

Only one mutation c.665T>C, p.(Ile222Thr) in *EIF2S3* has been reported previously in a family with three males affected by moderate to severe intellectual disability, microcephaly, and short stature [Borck *et al.* 2012]. One of them had also generalized seizures whereas his brother had postpubertal microgenitalism. Since this first description in 2012, no additional families with *EIF2S3* mutations have been published. *EIF2S3* encodes eIF2 γ . eIF2 γ forms with two distinct subunits (α and β) the eukaryotic translation initiation factor 2, eIF2, essential for protein synthesis. A ternary complex comprised of eIF2, GTP, and an initiator methionyl-tRNA (Met-tRNA_i), binds to the 40S ribosomal subunit and forms a preinitiation complex. This complex binds to a mRNA and starts protein translation.

To assess the biological impact of mutations in *EIF2S3*, we used the zebrafish vertebrate model, which is a well-established approach for the study of genetic microcephaly. By using MO oligonucleotides targeting translation of *eif2s3* gene, we showed that knockdown of the zebrafish *EIF2S3* ortholog reproduces some features of the human phenotype such as a small head size with small eyes and decreased body length. The observed features seem to be specific as the rescue experiments with human or zebrafish mRNA partially restored the phenotype.

We conclude that eukaryotic initiation factor eIF2 plays an essential role in brain development and that the variants found in *EIF2S3* are pathogenic. It is now important to identify additional individuals with *EIF2S3* mutations to delineate this rare but recognizable form of X-linked syndromic intellectual disability.

OFD1 IN MALES: CONGENITAL HEART DEFECT CAN BE INCLUDED IN ITS PHENOTYPIC SPECTRUM

A. BOUMAN¹, M. ALDERS¹, L. VAN LEEUWEN², N. THUIJS³ AND M. VAN MAARLE¹

¹ Clinical Genetics, AMC, The Netherlands.

² Department of Obstetrics and Gynaecology, AMC, The Netherlands.

³ Department of Pathology, AMC, The Netherlands.

E-mail for correspondence: a.bouman@amc.nl

Oral-facial-digital syndrome type 1 (OFD1; OMIM#311200) is an X-linked dominant disorder caused by mutations in the *OFD1* gene. This condition is characterized by facial anomalies and abnormalities of oral tissues, digits, brain and kidneys. Almost all affected patients are female, as OFD1 is presumed to be lethal in males mostly in the first or second trimester of pregnancy. OFD1 in liveborn males is rare, only four male OFD1 cases were published to date. In all cases the presence of a congenital heart defect (CHD) was observed. Here, we present a case of an affected male fetus with a pathogenic hemizygous de novo mutation in *OFD1* (c.2101C>T; p.(Gln701*)). Ultrasound examination demonstrated severe hydrocephalus, hypoplastic cerebellum and hypoplastic left ventricle of the heart. The pregnancy was terminated at 16 weeks of gestation because of poor prognosis. Post-mortem examination of the fetus confirmed severe hypoplasia of the left ventricle of the heart. We would like to create awareness that CHDs can be included in the phenotypic spectrum of male OFD1 syndrome, which should be considered a ciliopathy.

A BCOR VARIANT IN A MALE

M. DE RADEMAEKER¹, L. DEMEIRLEIR², A.C. HOUTMAN³, K. STOUFFS¹, B. CALJON¹, S. VAN DOOREN¹, D. CROES¹ AND K. KEYMOLEN¹

- 1 Centre for Medical Genetics, Reproduction and Genetics, Reproduction Genetics and Regenerative Medicine, Vrije Universiteit Brussel (VUB), UZ Brussel, Laarbeeklaan 101, 1090 Brussel, Belgium.
- 2 Department of Child Neurology, Vrije Universiteit Brussel (VUB), UZ Brussel, Laarbeeklaan 101, 1090 Brussel, Belgium.
- 3 Department of pediatric ophthalmology, Vrije Universiteit Brussel (VUB), UZ Brussel, Laarbeeklaan 101, 1090 Brussel, Belgium.

E-mail for correspondence: marjan.derademaeker@uzbrussel.be

We report on a boy born at 32 weeks after a pregnancy complicated with preeclampsia and intrauterine growth retardation. He presented dysmorphism and urogenital anomalies (cryptorchidism and hypospadias). Neonatal period was complicated by a persistent ductus arteriosus with severe pulmonary hypertension, pyloric stenosis MCOPS1 and severe feeding problems.

At the age of 5 years the boy presents dysmorphism (small eyes, bilateral epicanthus, synophris, long philtrum, thin upper lip, teeth abnormalities, clubbing finger nails and clinodactyly of the toes, radioulnar synostosis). He has intellectual disability. Cerebral MRI shows a thin corpus callosum, colpocephaly and some white matter disturbances. Feeding difficulties are still present and he is partially fed by a duodenal tube. He has a growth retardation.

A new variant in BCL6 corepressor gene (BCOR gene) was demonstrated. It is inherited from the mother. The BCOR gene on chromosome Xp11.4 is causative for the X linked dominant oculo-facio-cardio-dental syndrome (OFCD, Microphthalmia syndromic 2, MOCPS2). The phenotype is characterised by an ocular phenotype (such as microphthalmia), facial anomalies cardiac defects, dental irregularities and skeletal anomalies such as radioulnar synostosis seldom intellectual disability is associated. Pathogenic variants are deletions, truncating mutations and frame shift mutations with lethality in males.

Lenz microphthalmia syndrome is a X linked recessive condition. It comprises ocular anomalies (microphthalmia), facial dysmorphism, genitourinary and skeletal defects as well as developmental delay. The NAA10 gene on X q28 (MCOPS1) and BCOR are the two genes associated with the syndrome. Three male patients with a Lenz microphthalmia phenotype were previously reported having a missense mutation in BCOR.

Here we might present a fourth male patient with Lenz microphthalmia and a new missense variant in the BCOR gene. This is compatible with the earlier suggested hypothesis that females carrying mutations that result in a premature termination codon have OFCD and males carrying a missense mutation have Lenz microphthalmia syndrome.

Our patient presented a radioulnar synostosis, a feature associated in females with OFCD and seen in one boy with a mutation BCOR. When a male patient with ocular and urogenital anomalies and intellectual disability has radioulnar synostosis one should think of BCOR mutation analysis.

PHENOTYPIC OVERLAP IN GIRLS WITH *DDX3X* MUTATIONS AND TORIELLO-CAREY SYNDROME

N. DIKOW¹, M. GRANZOW¹, L.M. GRAUL-NEUMANN², S. KARCH³, K. HINDERHOFER¹, N. PARAMASIVAM^{4,5}, L.-J. BEHL⁶, L. KAUFMANN¹, C. FISCHER¹, C. EVERS¹, M. SCHLESNER⁵, R. EILS^{5,7}, G. BORCK⁸, C. ZWEIER, C.R. BARTRAM¹, J.C. CAREY¹⁰ AND U. MOOG¹

- ¹ Institute of Human Genetics, Heidelberg University, 69120 Heidelberg, Germany.
- ² Ambulantes Gesundheitszentrum Humangenetik, Charité Universitätsmedizin Berlin, Augustenburger Platz 1, 13353 Berlin, Germany.
- ³ Center for Child and Adolescent Medicine Pediatric Neurology, Heidelberg University Hospital, 69120 Heidelberg, Germany.
- ⁴ Medical Faculty Heidelberg, Heidelberg University, 69120 Heidelberg, Germany.
- ⁵ Division of Theoretical Bioinformatics, German Cancer Research Center (DKFZ), Im Neuenheimer Feld 280, 69120 Heidelberg, Germany.
- ⁶ Genomics and Proteomics Core Facility, High Throughput Sequencing, German Cancer Research Center, 69120 Heidelberg, Germany.
- ⁷ Department for Bioinformatics and Functional Genomics, Institute for Pharmacy and Molecular Biotechnology (IPMB) and BioQuant, Heidelberg University, 69120 Heidelberg, Germany.
- ⁸ Institute of Human Genetics, University of Ulm, 89081 Ulm, Germany.
- ⁹ Institute of Human Genetics, Friedrich-Alexander-Universität Erlangen-Nürnberg, Erlangen, Germany.
- ¹⁰ Division of Medical Genetics, Department of Pediatrics, University of Utah School of Medicine, UT 84132, United States of America.

E-mail for correspondence: nicola.dikow@med.uni-heidelberg.de

Recently, *de novo* heterozygous variants in *DDX3X* have been reported in 39 out of 2659 females with previously unexplained intellectual disability (ID). We report on the identification of *DDX3X* variants in two unrelated girls with clinical features of Toriello-Carey Syndrome. In patient 1, the recurrent variant c.1703C>T; p.(P568L) was identified when reconsidering X-linked *de novo* heterozygous variants in the whole exome sequencing data. In patient 2, the *DDX3X* variant c.1600C>G; p.(R534G) was detected with WES. Based on these data, *de novo* heterozygous *DDX3X* variants should be considered not only in undiagnosed females with ID, but also in individuals with a clinical diagnosis of Toriello-Carey syndrome. The most important features to clinically discern both syndromes might be the absence of telecanthus, laryngeal defects and corpus callosum agenesis, all core features of TCS, in the so far published *DDX3X* associated phenotype.

TWO NOVEL PATIENTS WITH AN XQ28 DUPLICATION EXCLUDING *FMR1* AND *MECP2*

O.M. VANAKKER¹, B. LAPAUW² AND A. GEERTS³

¹ Center for Medical Genetics, Ghent University Hospital, Ghent, Belgium.

² Department of Endocrinology, Ghent University Hospital, Ghent, Belgium.

³ Department of Gastro-enterology, Ghent University Hospital, Ghent, Belgium.

E-mail for correspondence: olivier.vanakker@ugent.be

Duplications of the Xq28 region of the X chromosome are a known cause of intellectual disability. The most common ones encompass the *MECP2* gene and cause a severe form of syndromic X-linked intellectual disability. Besides this well-characterized duplication syndrome, duplications involving other regions of Xq28 but not involving the *MECP2* gene have been described in phenotypes associated with intellectual disability. One of these is a duplication of the Xq27.3-q28 region, encompassing the *FMR1* gene and associated with hypogonadism, gynaecomastia, intellectual disability, short stature and obesity. We describe two brothers presenting with intellectual disability, short stature, obesity, hypogonadism and facial dysmorphism. They were found to harbor a 5.6 MB duplication of chromosome Xq28, overlapping with previously reported duplications but including neither the *MECP2* nor the *FMR1* gene. An overview will be given of the clinical characteristics of relevant Xq28 duplications reported in literature and the DECIPHER database to evaluate whether it is possible to establish genotype-phenotype correlations.

5-YEAR OLD BOY WITH INTELLECTUAL DISABILITY, DYSMORPHIC FACIAL FEATURES AND EEG ABNORMALITIES SHOWING AN INCREASED COPY NUMBER WITHIN THE REGION XQ28 CONTAINING A PARTIAL TRIPLICATION

J. KÖTTING¹, J. BEYGO¹, H.-J. LÜDECKE^{1,2}, K. BUITING¹ AND A. KÜCHLER¹

¹ Institut für Humangenetik, Universitätsklinikum Essen, Universität Duisburg–Essen, Essen, Germany.

² present address: Institut für Humangenetik, Universitätsklinikum Düsseldorf, Heinrich-Heine-Universität Düsseldorf, Düsseldorf, Germany.

E-mail for correspondence: Judith.Koetting@uk-essen.de

We report on a 4;9 year old boy, born to non-consanguineous parents from Kazakhstan, with ancestors from Germany. In the family history of both parents no one is known to show intellectual disability or any other relevant disease.

The pregnancy was complicated with difficult to control maternal hypertonia. He was born by planned C-section in gestational week 36, with normal measurements [weight: 2970 (P75-P90), length: 48cm (~P50), OFC: 34cm (~P75)]. Postnatally he was hospitalized for two weeks because of pre-term delivery with mild adaption difficulties. First gross motor milestones were reached in time, he was able to walk independently at age 16 months. He shows clumsiness and delay in fine motor skills. A mild hip dysplasia was successfully treated; a pes adductus was treated with insoles. Speech development is delayed. He is bilingual and can speak in sentences with 2 or 3 words but uses few vocabularies. He shows a short attention span and motor restlessness, ADHS was suspected. A Non-verbal IQ test was performed and showed an IQ of 67.

Further tests showed EEG-abnormalities (recurrent singular spike-wave-complexes in the left occipital region without generalization), but until now no event suspicious for seizures took place. He shows a progressive microcephaly. At age 4;9 years, his OFC was 47.8 cm (1.5 cm<P3), height: 108 cm (~P25) and weight 18kg (~P50). His facial features were characterized by hypertelorism, bilateral epicanthal folds, buffered upper eyelids, a broad nose and a full and everted lower lip.

Molecular investigations showed a normal result for the FMR1-repeat. In the array-analysis (Affymetrix Cytoscan HD Array), a dosage enhancement in Xq28 of ~270kb was detected containing several loci including the genes FLNA, TAZ and IKBKG. Detailed analysis of this region showed a complex gain with a duplicated segment of ~57.8 kb containing the FLNA-gene, followed by a triplication of a ~154.2 kb region containing the TAZ gene, again followed by a duplication of ~53.9 kb containing parts of the IKBKG gene. Quantitative real time PCR confirmed the duplication of the FLNA gene and the triplication of the TAZ gene in the boy and showed that the mother carried a dosage enhancement of the FLNA gene to three fold and a slight dosage enhancement of the TAZ gene.

Similar findings were published in the literature by Vandewalle *et al.* (2009) who showed families with triplication of the region Xq28 flanked by duplications comparable to our case. The borders of the dosage enhancement were marked by low copy repeat (LCR) regions that are abundant in the region Xq28. The borders of the centromeric duplication contain K-LCR elements and the borders of the telomeric duplication L-LCR elements. Non-allelic homologous recombination was assumed in a complex way leading to a partial triplication.

OCCIPITAL HORN SYNDROME IN A 57 YEAR-OLD MAN CARRYING A NOVEL NONSENSE MUTATION IN *ATP7A*: FAMILY REPORT AND LITERATURE REVIEW

M.T. BONATI¹, F. VERDE^{2,3}, U. HLADNIK⁴, L. CAMPANA², N. TICOZZI^{2,3}, L. MADERNA², C. COLOMBRITA², S. PAPA⁵, P. BANFI⁶ AND V. SILANI^{2,3}

¹ Clinic of Medical Genetics, IRCCS Istituto Auxologico Italiano, Milan, Italy.

² Neurology Unit and Laboratory of Neuroscience, IRCCS Istituto Auxologico Italiano, Milan, Italy.

³ Department of Pathophysiology and Transplantation, Dino Ferrari Center, University of Milan Medical School, Milan, Italy.

⁴ Laboratory of Medical Genetics, Mauro Baschirotto Institute for Rare Diseases, Costozza di Longare, Vicenza, Italy.

⁵ Unit of Diagnostic Imaging and Stereotactic Radiosurgery, Centro Diagnostico Italiano, Milan, Italy.

⁶ Don Carlo Gnocchi Foundation, Milan, Italy.

E-mail for correspondence: mt.bonati@auxologico.it

Occipital horn syndrome (OHS) takes its name from the pathognomonic occipital horn exostoses. It presents in early to middle childhood and is characterized predominantly by connective tissue and skeleton manifestations. Neurological features are instead predominant in the allelic classic Menkes Disease (MD). Both disorders, that represent the ends of a continuum, display X-linked recessive inheritance and are caused by mutations in the *ATP7A* gene (Xq21.1), coding for a copper-transporting ATPase localized in the trans-Golgi membranes. The phenotypes are related to deficient activity of copper-dependent enzymes. OHS and mild MD are usually the results of mutations that would result in a protein with residual activity, such as splice-site mutations producing also small amounts of normal protein.

We describe a cognitively normal OHS male in his late fifties, being much older than most OHS or mild MD patients reported in literature. The most disabling features were provoked by multiple vertebrae collapses that had occurred in his forties as a result of severe osteoporosis.

The patient's maternal uncle, who looked like him and died at 76 years, had difficulties in raising his upper limbs, a flexed knees posture, and underwent bladder surgery. The brother of his maternal grandmother was also reported to show movement difficulties with his upper limbs, including shirt-buttoning. The maternal uncle and the grandmother exhibited coarse hair. The maternal grandmother and his eldest sister (59 years old), who experienced premature teeth loss, also had the same cranio-facial features described in the proband.

The patient was found to carry a novel nonsense mutation (c.4222A>T, p.Lys1408*) in the second-last exon (22) of the *ATP7A*, causing the absence of the C-terminal 93 amino acids of the gene. Extension of the genetic analysis showed that his mother, the eldest of his two sisters, and her daughter carried the same genetic mutation.

Inheritance of the mutation from the patient's mother suggests that his maternal uncle, as well as the brother of his maternal grandmother, could also be affected by OHS. Indeed, they both experienced the typical limited movements of shoulders. Moreover, the presence of coarse hair in the proband's maternal uncle and grandmother, a possible obligate carrier of the c.4222A>T, further supports the hypothesis that two other males were also affected.

Dagenais *et al.* (2001) described a family affected by OHS in which a frameshift mutation at codon 1451 (exon 23) gave rise to a premature stop codon. Apart from the IQ, that fell into the low-average range, the proband's phenotype seems to overlap that of our patient.

With the exception of the described patient and the family report of Dagenais *et al.* (2001), all the identified *ATP7A* truncating mutations, either early or late, cause classic MD. Therefore, to our knowledge, the present report is the first to display a nonsense mutation and only the second to describe an *ATP7A* late truncation that results in OHS rather than in MD. Assuming that the two not genotyped males have the c.4222A>T mutation, the intra-familial variability in the severity of phenotype seems even wider in our family than that reported by Dagenais *et al.* (2001).

Although both transcripts lack the dileucine motif at positions 1487-1488, which is essential for the protein retrieval from the cell membrane to the trans-Golgi network, protein function is predicted to be not completely abolished, so that a mild phenotype ensues instead of the classic form of MD. In addition, the patient here reported moves the limit of truncating mutations with residual enzymatic activity from exon 23 to exon 22

MENTAL RETARDATION, (INNER) EAR MALFORMATIONS AND DYSMORPHISM; THE EXPANDING PHENOTYPE OF MED12 RELATED DISORDERS

A. VAN HAGEN¹, M. ELTING¹ AND S. JANSEN²

- 1 Department of Clinical Genetics, VU University Medical Center, Amsterdam, the Netherlands.
- 2 Department of Human Genetics, Donders Centre for Neuroscience, Radboud University Medical Center, Nijmegen, the Netherlands.

E-mail for correspondence: a.vanhagen@vumc.nl

MED12 encodes the mediator of RNA polymerase II transcription subunit 12 homolog protein (MED12), a subunit of the transcription regulating multiprotein Mediator complex. MED12 is involved in the Wnt/ β -catenin signaling, Gli3-dependent sonic hedgehog signaling and epigenetic silencing of neuronal gene expression imposed by the RE1-silencing transcription factor REST.

Mutations in MED12 cause three partially overlapping dysmorphic X-linked intellectual disabilities syndromes: Lujan-Fryns syndrome (also known as Lujan syndrome), FG syndrome (also known as Opitz-Kaveggia syndrome) and X-linked Ohdo syndrome (Maat-Kievit-Brunner Ohdo syndrome).

The existence of a fourth MED-12 related disorder characterized by severe intellectual disability and absent or deficient language is suggested and recently a boy with intellectual disability, Pierre Robin sequence, anomalous semicircular canals, a block vertebra and horizontal gaze paresis has been described.

We present several cases with a *MED12* mutation illustrating an expanding phenotype.

References

- Pontera P, Ottaviani V, Rogaia D *et al.* A Novel MED12 Mutation: Evidence for a fourth Phenotype. *Am J Med Genet* 2016;9999A:1-6.
- Prescott TE, Kulseth MA, Heimdal KR *et al.* Two male sibs with severe micrognathia and a missense variant in MED12. *Eur J Med Genet* 2016;59:367-372.
- Langley KG, Brouw J, Gerber RJ *et al.* Beyond Ohdo Syndrome: A Familial Missense Mutation Broadens the MED12 Spectrum. *Am J Med Genet* 2015;167:3180-3185.
- Graham JM and Schwartz CE. MED12 Related Disorders. *Am J Med Genet* 2013;161:2734-2740.

USEFULNESS OF SKIN BIOPSY IN THE GENETIC DIAGNOSIS OF MENTAL RETARDATION ASSOCIATED WITH SKIN PIGMENTARY LESIONS

Á. MARTÍN-RODRÍGUEZ¹, A. PRIETO-ABERASTURI², J. SÁNCHEZ¹ AND A. GONZÁLEZ-MENESES^{1,2}

¹ Hospital Universitario Virgen del Rocío, Sevilla (Spain).

² School of Medicine, University of Seville (Spain).

E-mail for correspondence: alvaromartin.md@gmail.com

Introduction: The aim of the present work is to determine the usefulness of conventional karyotyping in skin samples as a diagnostic tool in patients with neurological conditions and skin pigmentary mosaicism.

Methods: Patients affected with mental retardation, CNS malformations or other neurological abnormalities which also present skin pigmentary lesions were selected in our study. In their diagnostic approach they underwent genetic tests in blood samples and also a skin biopsy looking for chromosomal mosaicisms not found in normal karyotype.

Results: The results showed the presence of mosaic chromosomal abnormalities only in skin karyotype in 10 of the 30 patients observed (33%). Also, two more patients had abnormalities in blood and skin samples.

Conclusions: We have demonstrated that skin biopsy is an efficient diagnostic test to establish the etiology of conditions affecting skin and nervous system, especially when genetic studies in blood samples have shown no alterations.

UNEXPECTED DIAGNOSES AFTER WHOLE EXOME SEQUENCING

E. BIJLSMA, E. ATEN, D. FRANSEN VAN DE PUTTE, A. VAN HAERINGEN, N. DEN HOLLANDER, Y. HILHORST, S. KANT AND M. KOOPMANS, T. POTJER, M. HOFFER, C. RUIVENKAMP AND G. SANTEN

Department of Clinical Genetics, Leiden University Medical Center, The Netherlands.

E-mail for correspondence: e.k.bijlsma@lumc.nl

In many diagnostic DNA laboratories, whole exome sequencing (WES) is being incorporated as routine diagnosis for several indications. In our diagnostic DNA laboratory at the Leiden University Medical Centre, we were among the first to adopt this new technique. As expected, we were able to identify new disease genes and syndromes, which could not have been diagnosed without WES.

Unexpectedly however, diagnostic application also taught us some lessons we did not anticipate. Those can roughly be divided in the following categories:

- The patient has a known syndrome, but the doctor did not recognize this
- The patient has a phenotype that was not previously linked to the gene in which a mutation was found
- The patient has a clearly pathogenic mutation in a gene that does not (completely) explain his/her phenotype
- In case of negative WES results it does pay off to rethink the clinical diagnosis

In all of those categories, physical examination and interpreting the significance of the identified variants as well as the dysmorphic features has proven to be extremely important. This will be demonstrated in an interactive session, by showing and discussing some of the cases that have puzzled us the last years.

CLINICAL AND MOLECULAR SCREENING FOR THE FRAGILE X SYNDROME IN SPECIALIZED INSTITUTIONS IN KINSHASA, DR CONGO

A. LUMAKA^{1,2,3,4}, V. RACE¹, H. PEETER^{1S}, P. LUKUSA^{1,2,3,4} AND K. DEVRIENDT¹

¹ Centre for Human Genetics, University Hospital, University of Leuven, Belgium.

² Centre for Human Genetics, Faculty of Medicine, University of Kinshasa, DR Congo.

³ Department of Paediatrics, Faculty of Medicine, University of Kinshasa, DR Congo.

⁴ Institut National de Recherche Biomédicale, Kinshasa, DR Congo.

Screening for Fragile X syndrome (FXS) is essential in children with developmental delay or intellectual disability (ID). In addition, using clinical screening checklists remains of high interest in resource limited settings. So far, FXS has not been investigated in the centre of Africa. We aimed to gain insight into the prevalence of FXS, the distribution of CGG alleles, and to evaluate the usefulness of three checklists in specialized institutions in Kinshasa, DR Congo.

We recruited 80 males and 25 females from 6 specialised institutions in Kinshasa. We administered a questionnaire including items from the following FXS checklists: Hagerman, Maes and Guruju. FMR1 CGG repeats were assessed for every patient. Based on molecular results, we calculated the specificity of the 3 checklist.

About 37% of patients were referable for FX testing based on Hagerman's checklist, 35% for Maes' and 43.80% for Guruju's. Behavioural features were more prevalent than morphological ones. The mean CGG allele size was 28.55 ± 2.83 (ranges: 17-48). The 29 CGG was the most frequent allele (24.61%). No full mutation of premutation carrier was molecularly identify. Specificities were 62.86%, 64.76% and 56.5 % respectively for Hagerman, Maes and Guruju, respectively.

Given the presence of intermediate alleles, we anticipate that FXS is very likely to be present in the broader Congolese population. The distribution of CGG repeats and the number of CGG alleles are similar to other African studies. The 3 tested checklists showed poor performances and would need special adaptation for Congolese population.

THE CLINICAL RELEVANCE OF INTRAGENIC NRXN1 COPY NUMBER VARIANTS

N. COSEMANS AND H. PEETERS

Center for Human Genetics, University Hospitals Leuven, KU Leuven, 3000 Leuven, Belgium.

E-mail for correspondence: hilde.peeters@uzleuven.be

Neurexins (NRXNs) are cell-adhesion molecules concentrated at the synapses (**Fout! Verwijzingsbron niet gevonden.**). They are involved in synapse formation, differentiation and function, which makes them important in brain development and function. The extracellular part interacts with trans-synaptic molecules such as neuroligins and secreted molecules. The cytoplasmic tails are involved in intracellular protein-protein interactions and signaling processes through interaction with scaffold and signaling molecules such as synaptotagmin and CASK. The extracellular and intracellular domains are separated by a single-path transmembrane helix. NRXNs appear as two major isoforms, α -NRXNs and β -NRXNs, which contain identical transmembrane regions and cytoplasmic tails but differ in extracellular sequences.

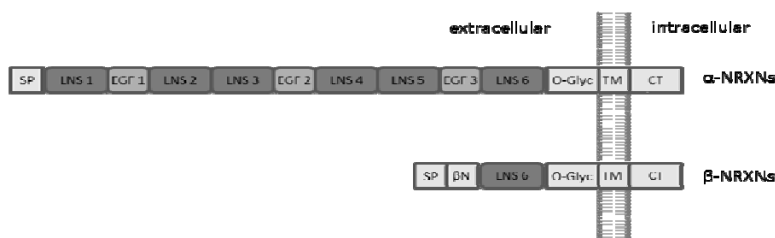


Figure 1: Structure of NRXNs. α -NRXNs are composed of an extracellular sequence containing a signal peptide (SP), six LNS domains separated by three EGF-like domains and followed by an O-glycosylation (O-Glyc) region, a single-path transmembrane helix (TM) and a short cytoplasmic tail (CT). β -NRXNs contain only one LNS domain, which is preceded by a β -NRXN-specific sequence (β N).

Rare intragenic copy number variants (CNVs) affecting *NRXN1* have been associated with neuropsychiatric disorders, such as developmental delay, language disorders, autism spectrum disorder, epilepsy, and schizophrenia and aspecific dysmorphic features. However it has been suggested that the phenotypic expressivity and penetrance may be related to the position of the variant (e.g. exonic versus intronic variants or variants affecting the beta isoform), no systematic data are available to support these hypotheses. The reason is that well described patient cohorts are rare and relatively small (less than 30 patients). Combining genotype-phenotype data from different studies and case reports is hampered by differences in ascertainment, by selective reporting (e.g. single case reports describing mainly exonic deletions) and by the lack of phenotypic data in large scale CNV studies. In addition, the exact CNV breakpoints have rarely been determined so that the delineation of the variant depends on the local resolution of the array platform. Despite these limitations, we performed a systematic literature review of the genotype and phenotype information of over 500 individuals. The distribution of rare and common intragenic *NRXN1* CNVs was studied in cases and controls and as a function of different phenotypic characteristics. In addition we present data on 35 patients with intragenic *NRXN1* deletions that have been identified in Leuven. The purpose of this study is to provide some guidelines to improve the clinical interpretation of intragenic *NRXN1* variants.

NEW CASE CONFIRMS THE ROLE OF CTNNB1 HAPLOINSUFFICIENCY IN INTELLECTUAL DISABILITY

J. DE GEYTER, K. STEINDL, B. ONEDA AND A. RAUCH

Institute of Medical Genetics, University of Zurich, Schlieren-Zurich, Switzerland.

E-mail for correspondence: degeyter@medgen.uzh.ch

We recently identified a 40Kb deletion on chromosome 3p22.1 encompassing the genes ULK4 and CTNNB1 in a 2 year old girl with distinctive facial features, fine sparse hair, microcephaly, development delay, hyperopia and strabismus.

The girl is the second born child of healthy non consanguineous parents. During gestation, fetal ultrasound showed an intrauterine growth retardation, but no invasive diagnostic was performed. The girl was born at term via sectio caesaria with good Apgar score. Birth parameters were at P3 for the head circumference and at P2 for weight but length was normal.

The clinical course was marked by global development delay, microcephaly (-2.9 SD) and truncal hypotonia. The ophthalmological examination revealed hyperopia and strabismus.

Joep de Ligt *et al.* (2012) described two children with severe intellectual disability, microcephaly and spasticity harboring two different intragenic CTNNB1 mutations (one nonsense and one frameshift), probably leading to a loss of function of the protein. Another publication reported a larger deletion in a single proband only containing ULK4 and CTNNB1 resulting in a very similar phenotype with microcephaly, progressive ataxia, spasticity, fine sparse hair and similar facial features (Dubruc *et al.*, 2014).

Our case confirms the clinical spectrum of CTNNB1 haploinsufficiency syndrome and supports the presence of a recognizable gestalt/phenotype.

HAPLOINSUFFICIENCY OF THE *NFIB* GENE IN PATIENTS WITH MILD INTELLECTUAL DISABILITY

I. SCHANZE¹, S. BOPPUDI¹, S. BERLAND², M. GÉRARD³, M. HOLDER-ESPINASSE^{4,5}, E. LACAZE³, S. MORGAN⁶, H. PEETERS⁷, F. PETIT⁴, D.T. PILZ⁸, I. WIELAND¹, J.-B. RIVIÈRE⁹, D. SCHANZE¹, L. FAIVRE^{9,10} AND M ZENKER¹

- 1 Institute of Human Genetics, University Hospital Magdeburg, Otto-von-Guericke University, Magdeburg, Germany.
- 2 Center for Medical Genetics and Molecular Medicine, Haukeland University Hospital, Bergen, Norway.
- 3 Department of Genetics, Hôpital Côte de Nacre, Caen, France.
- 4 Service de Génétique Clinique, Hôpital Jeanne de Flandre, Lille, France.
- 5 Department of Clinical Genetics, Guy's Hospital, London, United Kingdom.
- 6 Institute of Medical Genetics, University Hospital of Wales, Cardiff, UK.
- 7 Center for Human Genetics, University Hospital Leuven, KU Leuven, Leuven, Belgium.
- 8 West of Scotland Genetics Service, Queen Elizabeth University Hospital, Glasgow, UK.
- 9 EA 4271, Génétique des Anomalies du Développement; Université de Bourgogne, Dijon, France.
- 10 Centre de Génétique et Centre de Référence Anomalies du Développement et Syndromes Malformatifs de l'Interrégion Est et FHU TRANSLAD, Centre Hospitalier Universitaire Dijon, Dijon, France.

E-mail for correspondence: ina.schanze@med.ovgu.de

Recent reports have highlighted significant roles for members of the nuclear factor one (NFI) family of transcription factors in development of a number of organ systems particularly in neuronal development. It was recently shown that deletions or mutations in the family members *NFIA* and *NFIX* lead to human phenotypes including malformations and intellectual disability (ID). There is evidence to suggest also a role in numerous embryonic developmental processes including regulation of cortical development and callosal formation for *NFIB*. However in the current literature there are no reports of a human phenotype caused by anomalies of the *NFIB* gene.

Here we present six unrelated patients with overlapping microdeletions in the chromosomal region 9p23p22.2. *De novo* occurrence of the deletion could be proven in the 5 cases from which parental samples were available. The identified deletions have different breakpoints and range in size from 225 kb to 4.3 Mb. The smallest region of overlap of the six deletions narrows down the critical region to a genomic segment containing only the *NFIB* gene. Furthermore we present one patient with a *de novo* missense mutation within *NFIB*, predicted to be pathogenic by in silico prediction programs (SIFT/ Mutation Taster).

All patients presented with a similar phenotype of mild ID, muscular hypotonia, speech delay, attention deficit, and variable behavioral anomalies. For all patients growth parameters (body height, head circumference) were above the mean; one individual had absolute macrocephaly. The patients showed mild facial anomalies. Variable mild structural brain anomalies were observed including corpus callosum agenesis.

Based on these findings and the previously published functional data obtained from animal model we propose *NFIB* as a novel causative ID gene. We assume haploinsufficiency as the common disease-causing mechanism of the presented *NFIB* variations.

FURTHER DELINEATION OF A NOVEL 2Q11.1Q11.2 MICRODUPLICATION SYNDROME

S.M. AZZARELLO-BURRI¹, P. JOSET¹, J. ANDRIEUX², F. LOPES³, E.E. PALMER⁴, J.C. CZESCHIK⁵, B. DEMEER⁶, F. DUQUE⁷, A. KÜCHLER⁵, P. MACIEL³, B. PLECKO⁸, B. ONEDA¹ AND A. RAUCH¹

¹ Institute of Medical Genetics, University of Zurich, Zurich, Switzerland.

² Institut de Génétique Médicale, Hôpital Jeanne de Flandre, CHRU de Lille, Lille, France.

³ Life and Health Sciences Research Institute (ICVS), School of Health Sciences, University of Minho, Braga, Portugal; ICVS/3B's - PT Government Associate Laboratory, Braga/Guimarães, Portugal.

⁴ Genetics of Learning Disability Service, Waratah, NSW, Australia.

⁵ Institute of Human Genetics, Universitätsklinikum Essen, Essen, Germany.

⁶ Centre d'activité de génétique Clinique, CHU Amiens-Picardie, Amiens, France.

⁷ Centro de Desenvolvimento da Criança, Hospital Pediátrico, Centro Hospitalar e Universitário de Coimbra, Coimbra, Portugal.

⁸ Child Neurology, University Children's Hospital Zurich, Zurich, Switzerland.

E-mail for correspondence: anita.rauch@medgen.uzh.ch

Riley *et al.* Am J Med Genet 2015 recently reported an approximately 1.5 Mb recurrent duplication in 2q11.2 with variable outcome including a normal carrier mother and 3 patients with mild to moderate developmental delay, short stature and variable other features. We now observed 9 novel carriers from 6 families including two patients with de novo duplication. While 8 duplication carriers had low normal IQ or mild intellectual disability, one patient with de novo duplication suffered from profound developmental delay, microcephaly, and congenital heart defect. Under the suspicion of a second hit in the latter patient we performed trio exome sequencing which indeed revealed an additional disease causing mutation in a known ID gene. Our observation therefore indicates that the recurrent duplication 2q11.2 causes mild intellectual deficits only, while a more severe phenotype may be attributed to second hits.

A FAMILY OF KAGAMI-OGATA SYNDROME

R. NICOLESCU¹, J.-H. CABERG² AND S. BULK²

¹ CHR de la Citadelle, Service de Pédiatrie, Liège, Belgique.

² CHU de Liège, Service de Génétique Humaine, Liège, Belgique.

E-mail for correspondence: saskia.bulk@chu.ulg.ac.be

Kagami-Ogata syndrome is characterized by the presence of a bell-shaped thorax with a so-called coat-hanger configuration of the ribs, joint contractures, abdominal wall defects and polyhydramnios during pregnancy. In a minority of patients, a maternal deletion of the imprinted gene cluster in chromosome 14q32 is shown to be the cause. We present one family with an affected mother and two affected siblings presenting with classical Kagami-Ogata syndrome due to an inherited microdeletion in 14q32.2.

The index patient is a boy born after a pregnancy complicated by polyhydramnios from non-consanguineous Middle Eastern parents. At birth, he presented with a bell-shaped thorax, laryngomalacia, an umbilical hernia, joint contractures and dysmorphic features. Conventional karyotyping, DMPK1 and SMN1 testing, and metabolic analyses were normal. Cutaneous laxity suggested a cutis laxa syndrome, not confirmed with additional testing. During follow-up, the patient presented with a moderate to severe developmental delay. The mother presented with mild intellectual disability. Her previous medical history was unavailable. The familial history was unremarkable except for three cousins diagnosed with fragile X syndrome (FMR1 analyses normal).

Several years later, a healthy brother and an affected sister were born. The pregnancy of the sister was again complicated by polyhydramnios. A prenatal CGH-array did not show any abnormalities. At birth, she presented with a bell-shaped thorax, feeding difficulties and facial dysmorphisms. Additional testing revealed a primary hypothyroidism.

Postnatal molecular karyotyping revealed a maternal 200 kb deletion in 14q32.2 including DLK1 and MEG3. Additional testing confirmed a paternal UPD14 in both infants and their mother, confirming the diagnosis of Kagami-Ogata syndrome in all three. The healthy brother did not carry the deletion.

FATCO SYNDROME: FIBULAR HYPOPLASIA, TIBIAL CAMPOMELIA AND OLIGOSYNDACTYLY

L. DARDOUR¹, J. BRECKPOT¹, P. MOENS², C. OOSTERLYNCK³ AND K. DEVRIENDT¹

¹ Center for Human Genetics, University Hospitals & KU Leuven, Leuven, Belgium.

² Department of Orthopedics, University Hospitals & KU Leuven, Leuven, Belgium.

³ Pediatrician, AZ Groeninge, Kortrijk, Belgium Department of Electrical Engineering, Research, Belgium.

E-mail for correspondence: koenraad.devriendt@uzleuven.be

Fibular hemimelia is a rare congenital disorder, that can vary from mild fibular hypoplasia to fibular aplasia.

Fibular aplasia, tibial campomelia and oligosyndactyly (also termed FATCO syndrome) is a descriptive term for a syndrome with thusfar unknown aetiology.

We report the variable clinical findings of 4 patients with a probable diagnosis of FATCO syndrome.

In addition we present one patient with only fibular hemimelia and mild bowing of the tibia.

As previously reported, all cases we observed were sporadic, suggesting a dominant *de novo* mutation.

We will discuss the clinical presentation and differential diagnosis.

CONFIRMATION OF A DISTINCT CONDITION WITH SEVERE LIMB DEFICIENCY, (MIRROR) POLYDACTYLY AND VARIABLE ORGAN MALFORMATIONS

P. THILOBO LUKUSA¹, L. DARDOUR¹, L. LEWI², P. MOERMAN³ AND K. DEVRIENDT¹

¹ Center for Human Genetics,

² Department of Obstetrics,

³ Department of Pathology, University Hospitals & KU Leuven, Leuven, Belgium.

E-mail for correspondence: koenraad.devriendt@uzleuven.be

This was the first pregnancy of healthy, unrelated parents.

Ultrasound examination revealed the presence of multiple structural malformations, for which a termination of pregnancy was done at a gestational age of 14 weeks. Ultrasound anomalies included megacystis - megalourethra – with herniation of the bladder into the thorax (and suspected diaphragmatic hernia); shift of the heart to the right side, solitary kidney on the left, absence of the left arm, single umbilical artery, talipes of the left foot with suspicion preaxial polydactyly.

Pathological examination confirmed the complete absence of the left arm. The left foot showed a heptadactyly with syndactyly 2-3. Right hand and right foot were normal. The external genitalia comprised a dilated phallus-like structure, and the sex could not be determined macroscopically. There was anal atresia.

Internal examination revealed an absent right lung, absent spleen, short bowel with absent appendix, persistent urogenital sinus with hydrometrocolpos, crossed ectopia with fusion of the right kidney and single umbilical artery.

Microarray-CGH revealed a normal female molecular karyotype.

This highly unusual combination of malformations is almost identical to those described by Martinez-Frias *et al.* AJMG 1997. Their case 2 also has unilateral lung agenesis, anal atresia, amelia of the left upper limb and left heptadactyly of the left foot. In addition, there were urogenital anomalies. Features lacking in our case were segmentation anomalies of the spine, even though no radiographs were available from the present fetus.

Martinez-Frias report another case with similar malformations, and discuss the similarities with the two siblings reported by Urioste *et al.* 1996.

The present case confirms that these five cases may represent a novel distinct entity. The etiology is unknown. All cases were sporadic so far, but in one of them, the parents were consanguineous.

References

Martinez-Frias ML, *et al.* Severe limb deficiencies, vertebral hypersegmentation, and mirror polydactyly: two additional cases that expand the phenotype to a more generalised effect on blastogenesis. *Am J Med Genet* 1997; 73: 205-209.

Urioste M, Lorda-Sanchez I, Blanco M, Buron E, Aparicio P, Martinez-Frias ML. Severe congenital limb deficiencies, vertebral hypersegmentation, absent thymus and mirror polydactyly: a defect expression of a developmental control gene? *Hum Genet* 1996; 97: 214-217.

TAR SYNDROME WITH OROFACIAL CLEFTING - 30 YEARS FOLLOW-UP

A.T. MIDRO¹, J. BORYS², E. HUBERT², T. DAWIDZIUK¹, E. WASILEWSKA³, J. SKOWRONSKI⁴, E. TARASÓW⁶, B. PANASIUK¹, E.M. OLECH⁶ AND A. JAMSHEER⁶

¹ Department of Clinical Genetics, Medical University, Bialystok, Poland.

² Maxillo-Facial Surgery of Clinic, Medical University, Bialystok, Poland.

³ Clinic of Haematology, Medical University, Bialystok, Poland.

⁴ Orthopaedic Clinics, Medical University, Bialystok, Poland.

⁵ Radiology Clinic, Medical University, Bialystok, Poland.

⁶ Department of Medical Genetics, Poznan University of Medical Sciences, Poznan, Poland.

E-mail for correspondence: alinamidro@gmail.com; midro@umb.edu.pl

We present a natural history of 30 year-old man with Thrombocytopenia – absent radius syndrome (TAR) due to a *de novo* 1q21.1 microdeletion and paternal point mutation of *RBM8A* (c.67+32G>C). Unusual association with orofacial clefting has been observed. The short stature, focomelia, normal thumbs among five fingers of hands, and some defects of lower limbs with associated thrombocytopenia and distinctive craniofacial features included hypertelorism, epicanthus, low set ears, broad nasal roots were basis of clinical diagnosis at age of 5 months. As a main diagnostic tool for quantitative evaluation of morphological phenotype a protocol of 800 well defined and systematised traits (by Stengel-Rutkowski with own modifications) was used. Analysis of his morphological and clinical phenotype has been performed at the age of 5 months, 2, 9, 20 and 30 years. The progression of clinical changes in the form of skeletal dysplasia which affects skull, spine, lower limbs, fingers of hands and foot have been observed and described in details.

BALLER-GEROLD, RAPADILINO AND ROTHMUND-THOMSON SYNDROMES: CASE REPORTS AND MUTATIONS DETECTED IN OUR PATIENT COHORT

J KOHLHASE¹, G SCHMIDT² AND W BOROZDIN¹

¹ Center for Human Genetics, Freiburg, Germany.

² Praxis für Humangenetik, Frankfurt, Germany.

E-mail for correspondence: jkohlhase@humangenetik-freiburg.de

Baller-Gerold syndrome (BGS) is characterized by coronal craniosynostosis, radial ray defects, growth retardation and poikiloderma. The clinical picture overlaps with Rothmund-Thomson syndrome (RTS) and RAPADILINO syndrome, both caused by mutations in *RECQL4*. RTS is characterized by poikiloderma, sparse hair, eyelashes, and/or eyebrows, small stature, skeletal and dental abnormalities, cataracts and an increased risk for cancer, especially osteosarcoma. RAPADILINO syndrome (acronym for RAdial ray defects, PAtellar anomalies, DIarrhea, Little size, NOse slender and NOrmal intelligence) is characterized by irregular pigmentation with café au lait macules (but no poikiloderma), small stature, palate defects, radial ray defects, patellar hypoplasia, and GI abnormalities. Here we present the results of mutation analysis in *RECQL4* in patients with those diagnoses in our laboratory and describe selected cases.

HEPATOBLASTOMA IN A FEMALE WITH SIMPSON GOLABI BEHMEL SYNDROME: SHOULD WE MONITOR FEMALES WITH SGBS AS WE DO FOR MALES ?

D. HAYE¹, E. AMOUYAL¹, C. BAUMANN¹, Y. CAPRI¹, S. ROSSIGNOL², M.-P. MOIZARD³, A. VERLOES⁴ AND L. PERRIN¹

¹ Department of Genetics, APHP-Robert Debré University Hospital, and Paris VII-Denis Diderot Medical School Paris, France.

² Department of Genetics, APHP-Trousseau University Hospital, France.

³ Department of Genetics, Tours University Hospital, France.

⁴ Sorbonne-Paris Cité University, Denis Diderot Medical School, and INSERM UMR 1141, France.

Simpson Golabi Behmel Syndrome (SGBS) (OMIM 312870) is a rare X-linked syndrome characterized by pre- and post-natal overgrowth, macrocephaly, characteristic facies, organomegaly, variable congenital malformations, mild/moderate intellectual deficiency and increased tumoral risk. It is caused by point mutations or genomic rearrangements in the glypican 3-gene (GPC3) that encodes a heparane sulphate proteoglycan, highly expressed in the mesodermal embryonic tissues and involved in the control of cell growth and cell division.

We report on two girl sibs and their mother with SGB. The first girl was born at 36 WG, without macrosomia. She had a macroglossia that spontaneously regressed. She died from unexplained post surgical complications of a hepatoblastoma at age three. Her sister was born at 37 WG after a pregnancy marked polyhydramnios. She had macrosomia, macroglossia, nephromegaly (+2SD) and diffuse hepatomegaly. Wiedemann Beckwith syndrome was excluded. A novel c.213_214insC heterozygous missense insertion (p.Q23TfsX46) was identified in exon 1 GPC3 by Sanger sequencing in the family. X inactivation was not biased. The patient is currently followed on a yearly basis with abdominal ultrasound scan, and screened for tumoral markers and urinary catecholamins. The mother is asymptomatic. Females with mutation in GPC3 can express SGBS. Dysmorphic features, macrosomia, diaphragmatic hernia, developmental delay and mild intellectual delay have been reported. Lyonisation has been proposed as the underlying mechanism for variable expression of SGBS in female patients (Yano 2011). SGBS predisposes to embryonal tumors, as Wilms tumor, hepatoblastoma and medulloblastoma. In males, the risk of embryonal tumor has been estimated at 8% in males (Cottureau 2013). Cancers were only reported in two unrelated affected females: one low-grade ovarian carcinoma, and one with breast cancer (the imputability of which remaining dubious). Guidelines for neoplasia screening have been proposed for males, although their benefit remains to be evaluated. Observation of hepatoblastoma in females with SGB raises the question of applying the same policies in both sexes.

Participants 27th European Dysmorphology Meeting 2016

| Name | First name | E-mail address |
|------------------|--------------|------------------------------------|
| ADDOR | Marie-Claude | Marie-Claude.Addor@chuv.ch |
| AVELA | Kristiina | kristiina.avela@hus.fi |
| BARTHOLDI | Deborah | deborah.bartholdi@insel.ch |
| BAYAT | Allan | allan.bayat@regionh.dk |
| BIJLSMA | Emilia | E.K.Bijlsma@lumc.nl |
| BLOCH-ZUPAN | Agnes | Agnes.Bloch-Zupan@unistra.fr |
| BONATI | Maria Teresa | mt.bonati@auxologico.it |
| BOTTANI | Armand | armand.bottani@unige.ch |
| BOUMAN | Arjan | a.bouman@amc.uva.nl |
| BRECKPOT | Jeroen | jeroen.breckpot@uzleuven.be |
| BRICHOUX-BOUCHER | Elise | ebrischouxboucher@chu-besancon.fr |
| BULK | Saskia | saskia.bulk@chu.ulg.ac.be |
| CALLEWAERT | Bert | Bert.Callewaert@Ugent.be |
| DARDOUR | Leila | leila.dardour@uzleuven.be |
| DE GEYTER | Julie | degeyter@medgen.uzh.ch |
| DE MAN | Stella | SdMan@amphia.nl |
| DE RADEMAEKER | Marjan | Marjan.DeRademaeker@uzbrussel.be |
| DEVRIENDT | Koen | Koen.Devriendt@med.kuleuven.be |
| DIKOW | Nicola | Nicola.Dikow@med.uni-heidelberg.de |
| DIMITROV | Boyan | boyanivanov.dimitrov@uzbrussel.be |
| FAUTH | Christine | Christine.Fauth@i-med.ac.at |
| FLEISCHER | Nicole | nicole@fdna.com |
| GARAVELLI | Livia | livia.garavelli@asmn.re.it |
| GOGOLL | Laura | gogoll@medgen.uzh.ch |
| HAYE | Damien | damien.haye@aphp.fr |
| IVANOVSKI | Ivan | ivan.ivanovski@asmn.re.it |
| JEANNE | Médéric | mederic.jeanne@gmail.com |
| KEYMOLEN | Kathelijn | Kathelijn.Keymolen@uzbrussel.be |
| KIBAЕК NIELSEN | Irene | irene.kibaek.nielsen@rn.dk |
| KOHLHASE | Jürgen | jkohlhase@humangenetik-freiburg.de |
| KÖTTING | Judith | Judith.Koetting@uk-essen.de |
| KUECHLER | Alma | alma.kuechler@uni-due.de |
| LACOMBE | Didier | didier.lacombe@chu-bordeaux.fr |
| LEDERER | Damien | damien.lederere@ipg.be |
| LUKUSA TSHILOBO | Tshilobo | p.lukusat@gmail.com |
| LUMAKA ZOLA | Aimé | aime.lumaka@uzleuven.be |
| MARTIN-RODRIGUEZ | Álvaro | alvaromartin.md@gmail.com |
| MATULEVICIENE | Ausra | ausra.matuleviciene@mf.vu.lt |
| MIDRO | Alina | alinamidro@gmail.com |
| MITTER | Diana | diana.mitter@medvz-leipzig.de |

| | | |
|-----------|-----------|------------------------------|
| MOORTGAT | Stéphanie | stephanie.moortgat@ipg.be |
| PEETERS | Hilde | Hilde.Peeters@uzleuven.be |
| RAUCH | Anita | anita.rauch@medgen.uzh.ch |
| SCHANZE | Ina | ina.schanze@med.ovgu.de |
| STEINDL | Katharina | steindl@medgen.uzh.ch |
| STOLL | Claude | cstoll@unistra.fr |
| STUMPEL | Connie | c.stumpel@mumc.nl |
| TOUTAIN | Annick | annick.toutain@univ-tours.fr |
| VAN HAGEN | Annet | a.vanhagen@vumc.nl |
| VANAKKER | Olivier | Olivier.vanakker@ugent.be |
| VERLOES | Alain | alain.verloes@gmail.com |
| ZENKER | Martin | martin.zenker@med.ovgu.de |